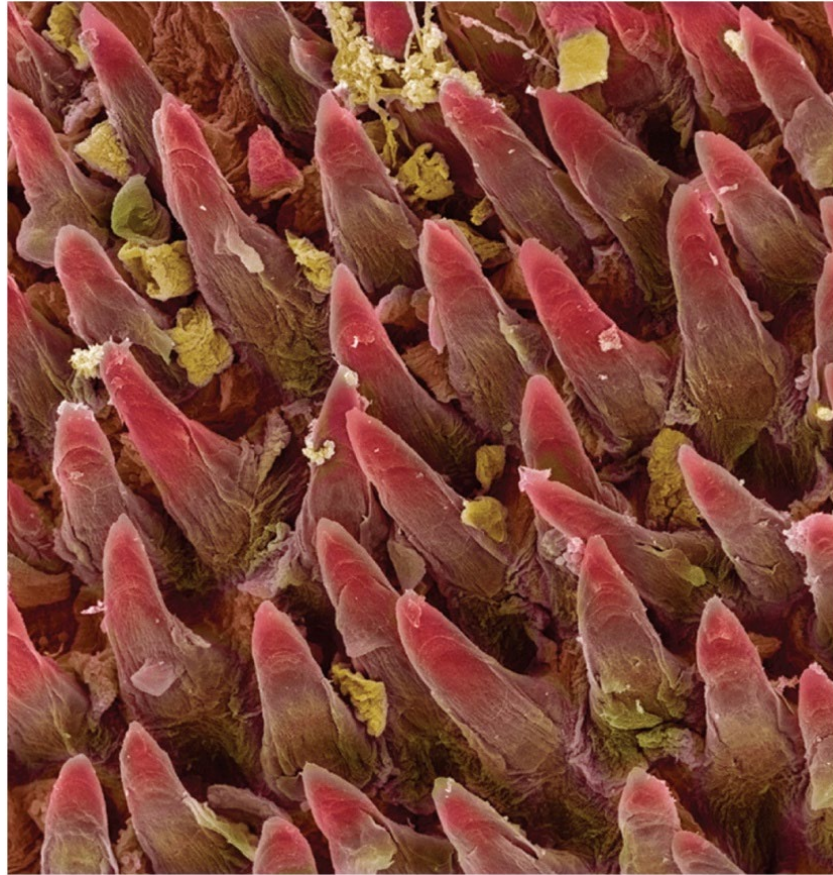
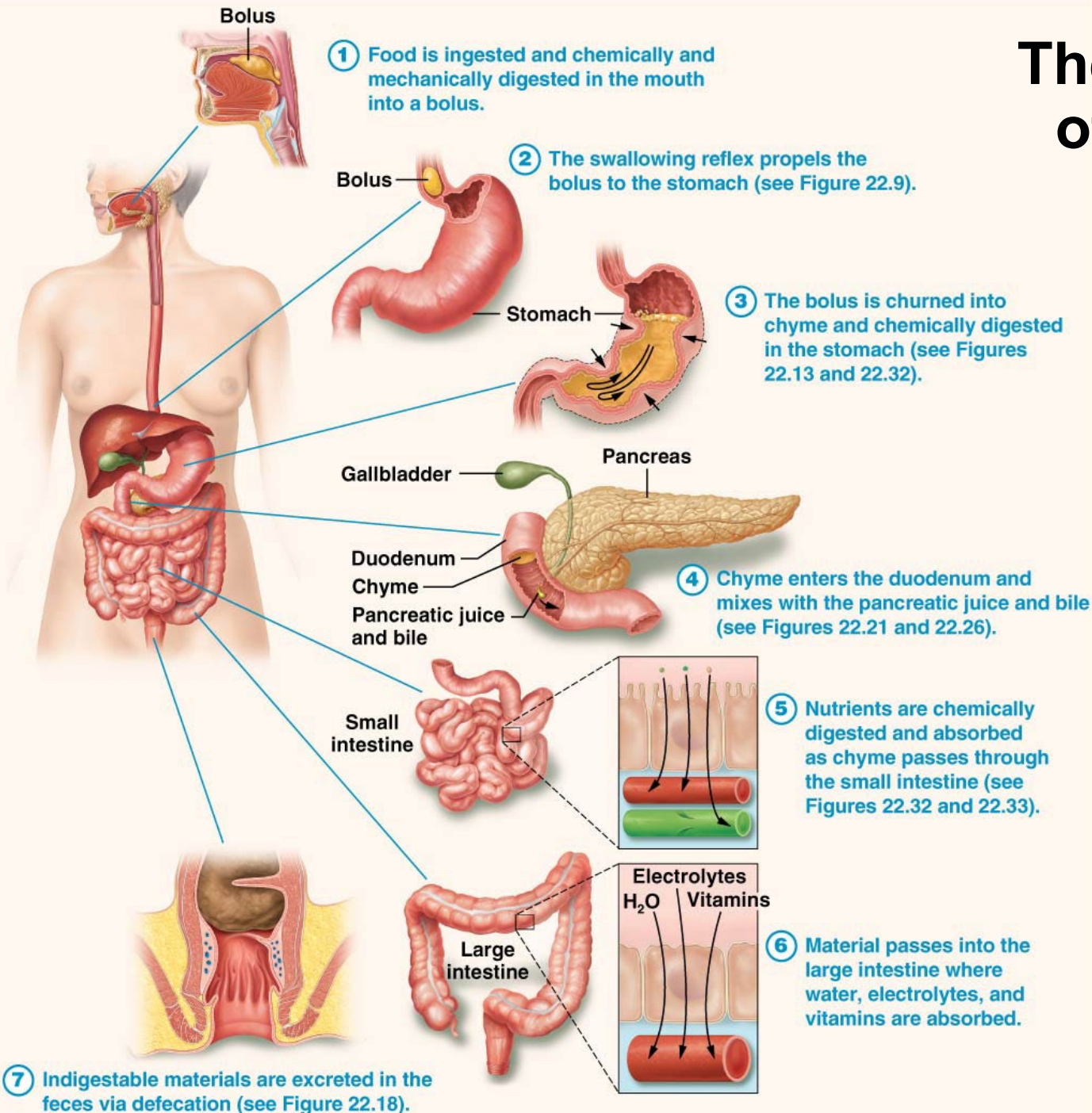


# The Digestive System (C25.1)



# The Big Picture of Digestion.



# General Structure of the Digestive System

## Two Divisions

**1 - Digestive tract** (also called the alimentary canal)

30 foot long muscular tube extending from mouth to anus

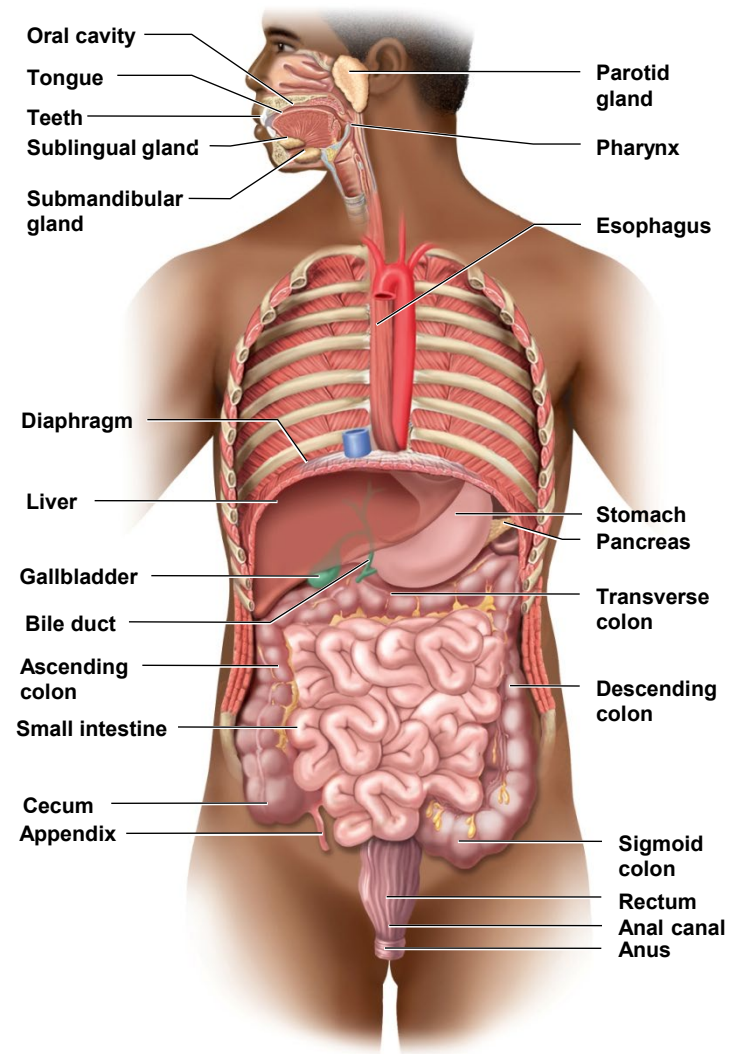
**mouth, pharynx, esophagus, stomach, small intestine, and large intestine**

gastrointestinal (GI) tract is the stomach and intestines

**2 - Accessory organs**

teeth, tongue, salivary glands, liver, gallbladder, and pancreas

Copyright © The McGraw-Hill Companies, Inc. Permission required for reproduction or display.



# Digestive System Functions

---

## Six Functions

**ingestion** - selective intake of food

**digestion** – mechanical and chemical breakdown of food into a form usable by the body

**absorption** - uptake of nutrient molecules into the epithelial cells of the digestive tract and then into the blood and/or lymph (crossing mucosa)

**compaction** - absorbing water and consolidating the indigestible residue into feces

**defecation** - elimination of feces

**regulation** - coordinate reflexes within and between the intestine and other organs (including brain)

# General Anatomy

---

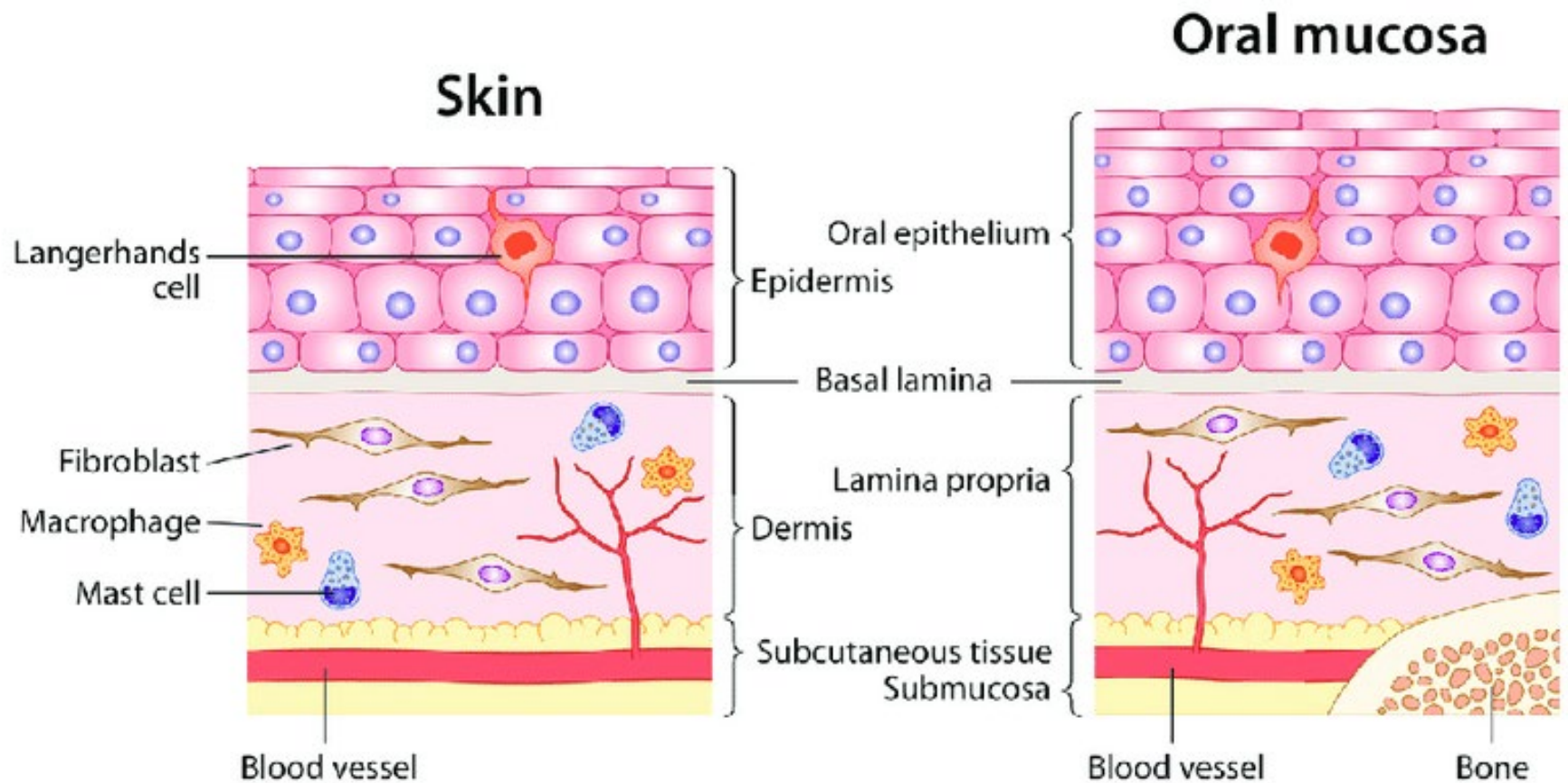
Digestive tract is a tubular structure

Digestive tract is open to the environment at both ends

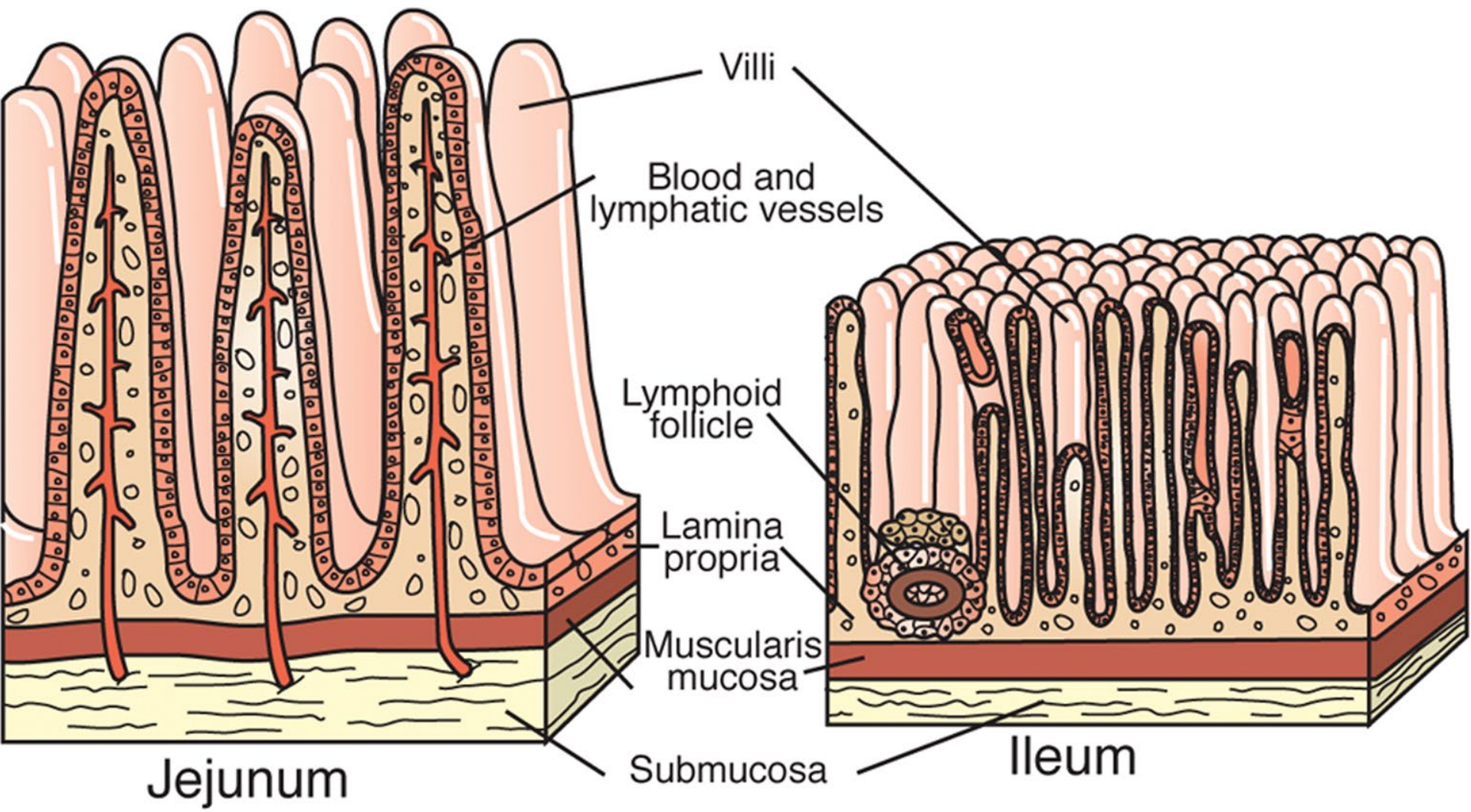
Material in lumen does not cross the mucus membrane to enter the body tissues

The food residue never crosses the mucosa

Nutrients in the GI lumen are outside of the body until they cross the mucosa of the absorptive cells and move into the body tissues



- > Stratified epithelium.
- > Langerhans cells = dendritic cells.



Simple epithelium.

# Sphincter Muscles Regulate Movement Through Digestive Tract

---

Sphincter muscles are “mostly” smooth muscle that regulate passage of food (i.e. bolus / chyme / fecal matter) through the digestive system

(What nervous system regulates smooth muscle?)

**Fascicles** arranged in circular pattern around tubular structure = sphincter muscles /// constrict to close movement through tubular structure

Sphincter muscles are smooth muscle with **one exception** - the “external anal sphincter” is a skeletal muscle

List of sphincter muscles along alimentary canal

- Upper esophageal sphincter (physiologic)
- Lower esophageal sphincter (cardiac)
- Pyloric sphincter
- Ileocecal valve (not a true sphincter muscle)
- Internal anal sphincter
- External anal sphincter (skeletal muscle)

# The Digestive System

---

Most **nutrients** we eat cannot be used in their existing form

Food must be physically **broken down into smaller “chucks”**, then.....

Macromolecules (polymers) covalent bonds hydrolyze to make monomers

Digestion does not break apart molecules into individual atoms

The digestive system is essentially a **“disassembly line”** // break down nutrients into a form that can be transported across the GI tract mucosa and then used by the body

- **nutrients must be absorbed across the mucosa**
- **then distributed to the cells and tissues of the body**

# Two Types of Digestion

## Mechanical VS Chemical

---

### Mechanical digestion

- the physical breakdown of food into smaller particles
- cutting and grinding action of the teeth
- churning action of stomach and small intestines
- exposes more food surface to the action of digestive enzymes

# Two Types of Digestion

## Mechanical VS Chemical

---

### Chemical digestion

a series of hydrolysis reactions (ie break covalent bonds) to turn dietary macromolecules into their monomers

carried out by **digestive enzymes** produced by salivary glands, stomach, pancreas and small intestine

#### Results:

polysaccharides into **monosaccharides**

proteins into **amino acids**

fats into **monoglycerides and fatty acids**

nucleic acids into **nucleotides**

Note: Some nutrients are present in a usable form in ingested food /// absorbed without being digested - vitamins, free amino acids, minerals, cholesterol, and water

# Pharynx

---

Common term is throat

- A muscular funnel that connects oral cavity to esophagus and allows entrance of air from nasal cavity to larynx
- Where the digestive and respiratory tracts intersect
- **Pharyngeal constrictors** (superior, middle, and inferior) - circular muscles that force food downward during swallowing
- When **not swallowing**, the superior constrictor remains contracted to exclude air from the esophagus /// this constriction is considered to be the **upper esophageal sphincter** although it is not an anatomical feature
- Disappears at the time of death when the muscles relax, so it is a physiological sphincter, not an anatomical structure

# Stomach

**Mechanical digestion** breaks up bolus, turns solid food into a liquid, and begins chemical digestion of protein and fat

**The bolus is turned into chyme in the stomach** – soupy or pasty mixture of semi-digested food in the stomach

- **In the stomach**

Salivary amylase / deactivated by gastric acid

Lingual and gastric lipases / activated by gastric acid

Gastric HCl denatures protein

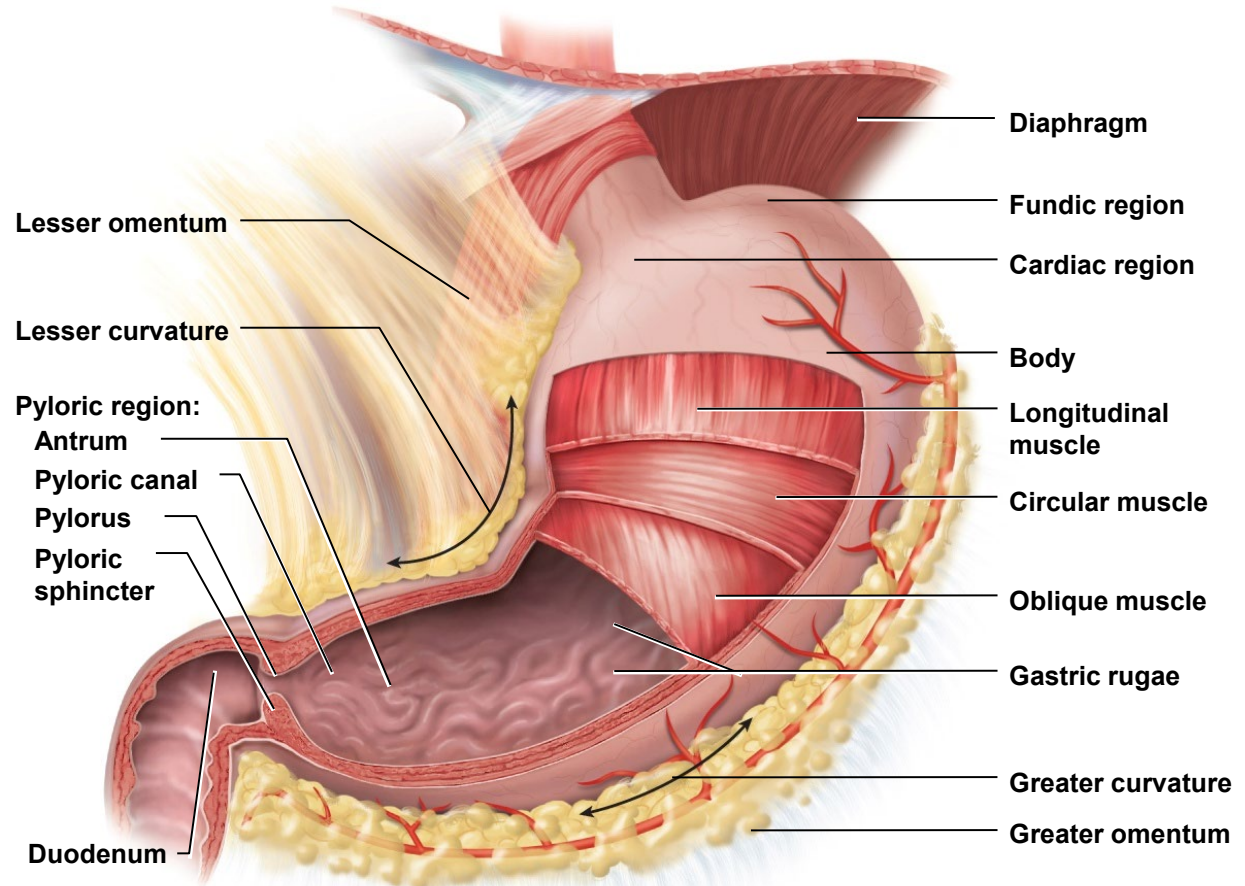
Gastric Pepsinogen converted by gastric HCl into active pepsin

- **Most chemical digestion occurs after the chyme passes into the small intestine (99%)**

# Stomach

The stomach has three layers of smooth muscle.

All other regions of the GI tract only has an inner circular layer and outer longitudinal layer.



bulge of fundus, narrowing of pyloric region, thickness of pyloric sphincter, and greater and lesser curvatures

# Stomach

---

Muscular sac in upper left abdominal cavity immediately inferior to the diaphragm

Primary function is for **food storage and designed to release “small volumes” into duodenum**

- internal empty volume is about **50**
- **1.0 – 1.5 L volume after a typical meal**
- up to **4 L when extremely full** and will extend nearly as far as the pelvis
- takes approximately **4 hours** to clear after normal meal
- antrum hold 30 ml
- **3 ml** of chyme released into duodenum per peristaltic contraction

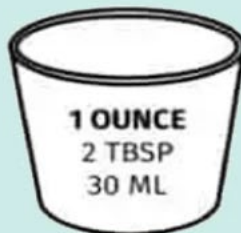
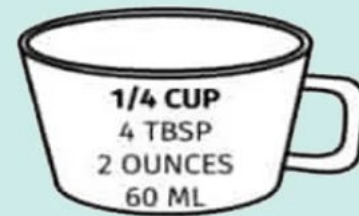
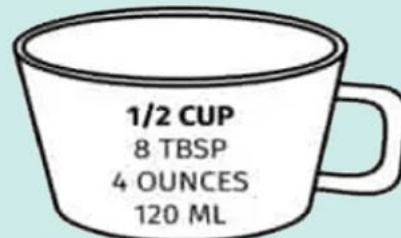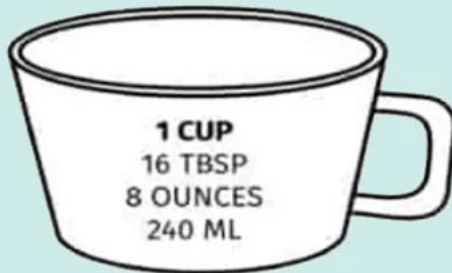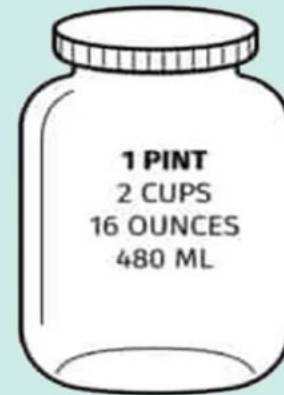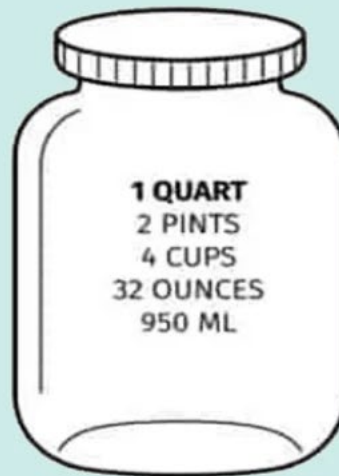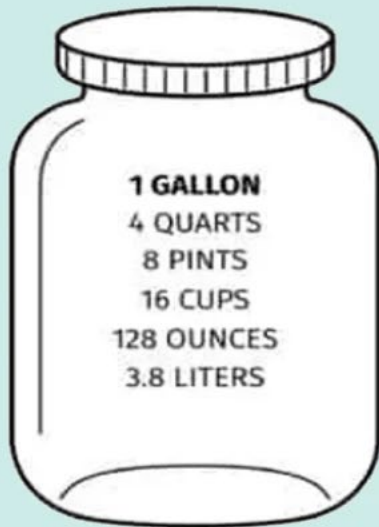Teaspoon Volumes

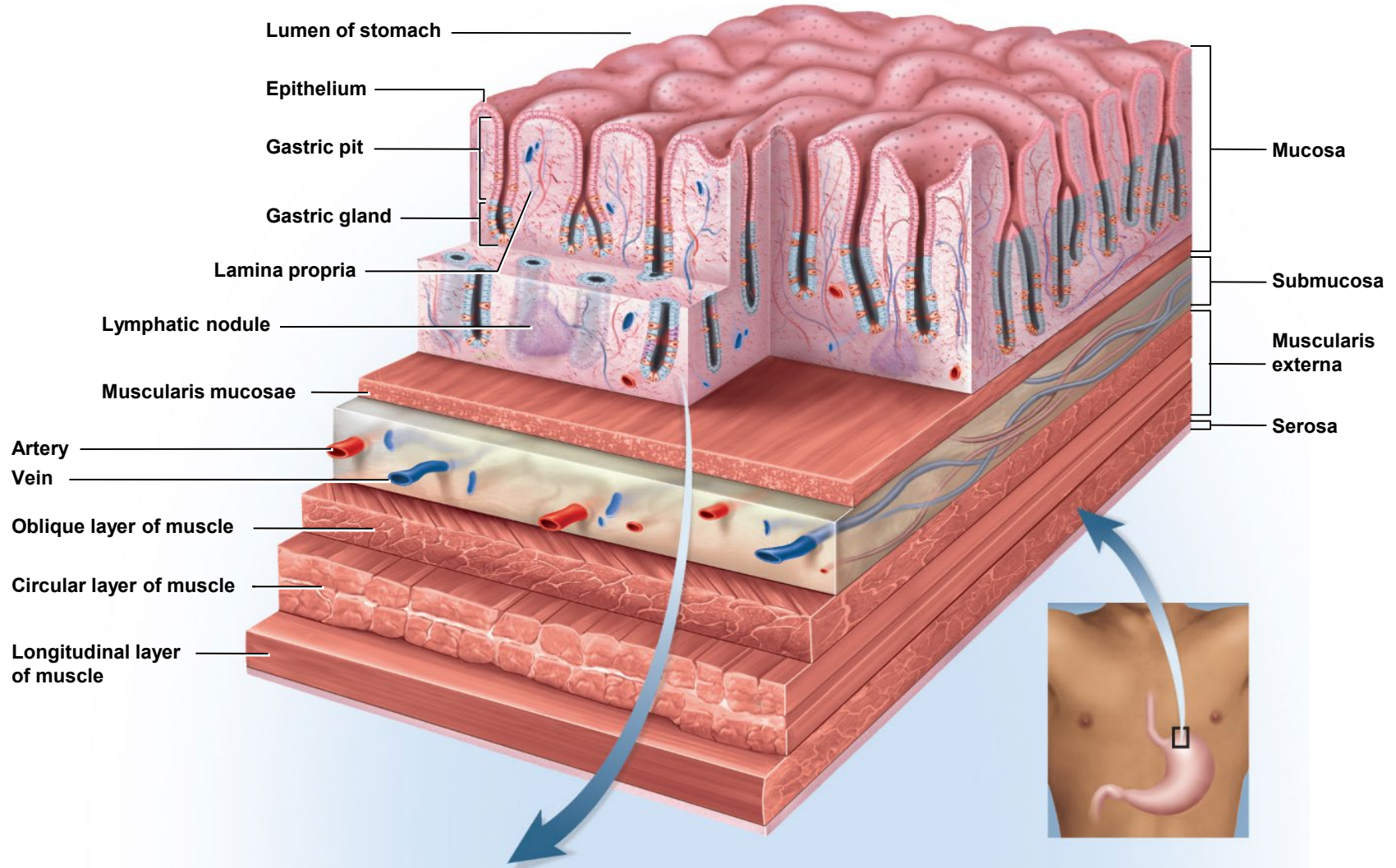




1.5 Liters



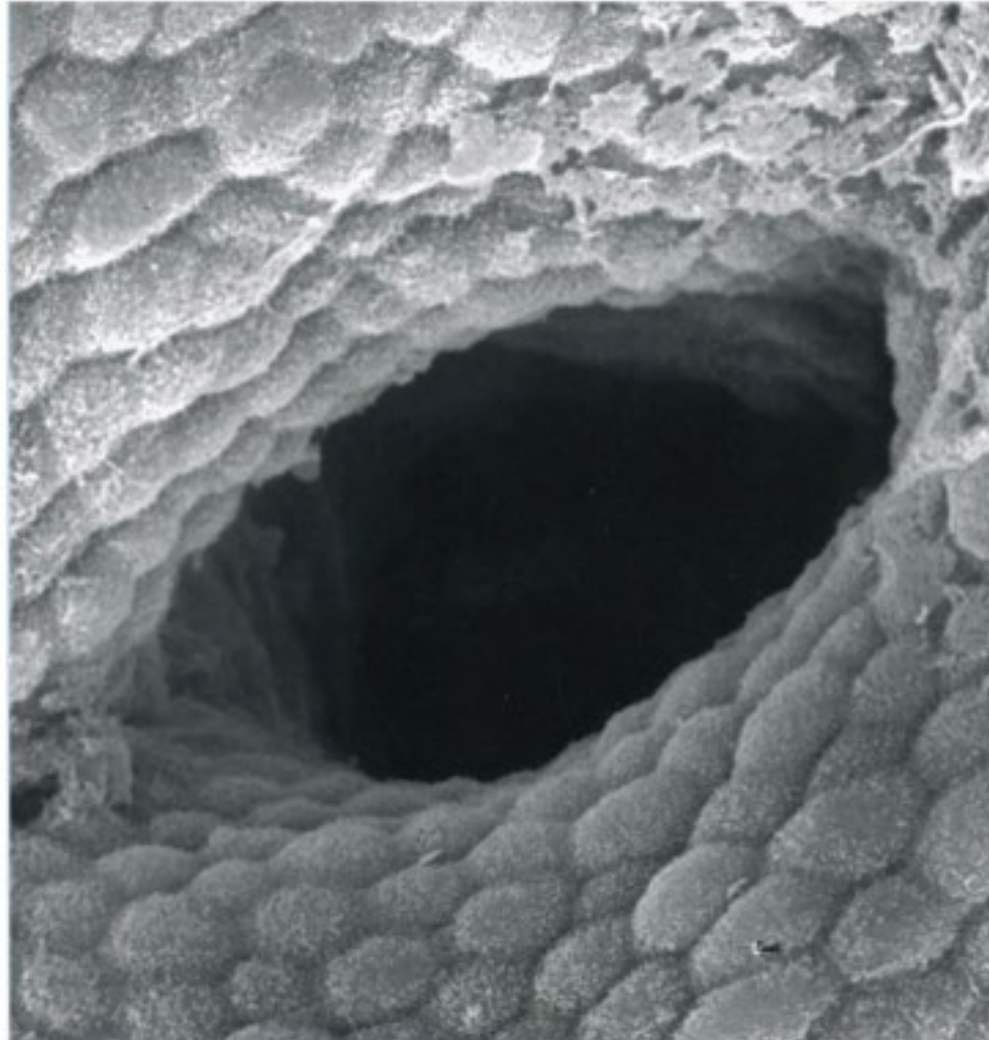
# Microscopic Anatomy



**Stomach wall**

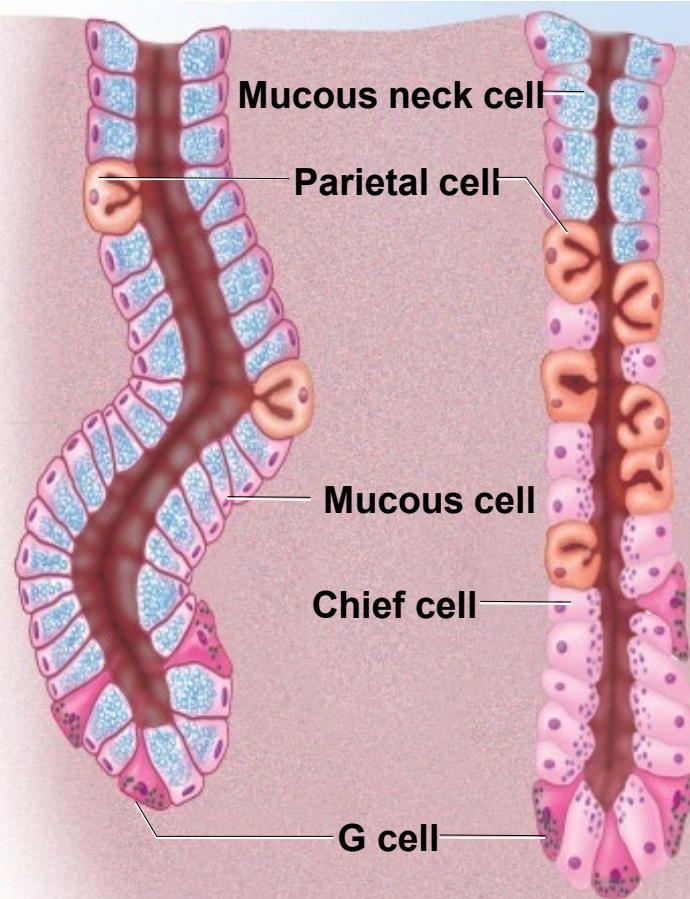
# Opening of Gastric Pit

Copyright © The McGraw-Hill Companies, Inc. Permission required for reproduction or display.



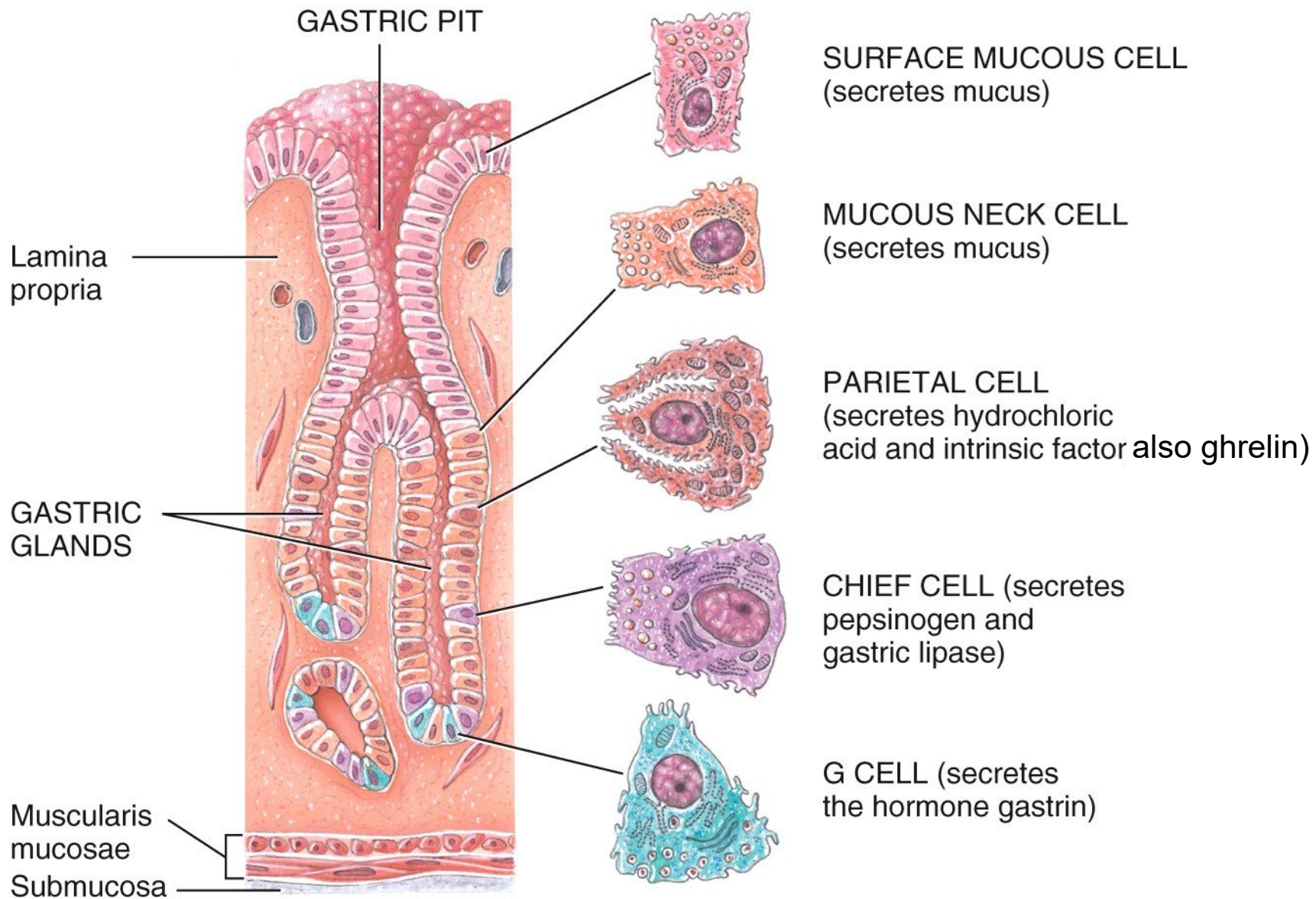
Visuals Unlimited

# Pyloric and Gastric Glands



(b) Pyloric gland

(c) Gastric gland



(b) Sectional view of the stomach mucosa showing gastric glands and cell types

# How Does the Stomach Protect Itself From Digestion?

---

Stomach is protected by three ways from the harsh acidic and enzymatic environment inside the stomach

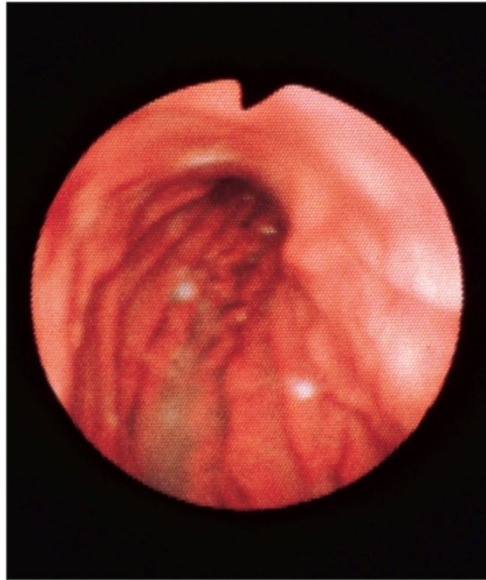
–**mucous coat** – thick, highly alkaline mucus resists action of acid and enzymes

–**tight junctions** - between epithelial cells prevent gastric juice from seeping between them and digesting the connective tissue of the lamina propria and beyond

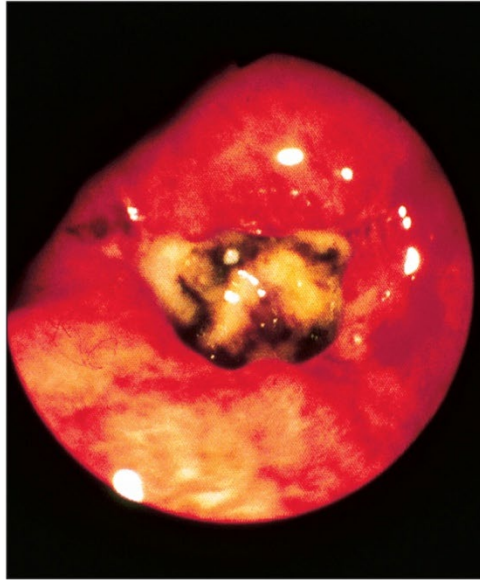
–**epithelial cell replacement** – stomach epithelial cells live only **3 to 6 days** // sloughed off into the chyme and digested with the food // replaced rapidly by cell division in the gastric pits

Breakdown of these protective measures can result in inflammation and peptic ulcer

# Healthy Mucosa and Peptic Ulcer



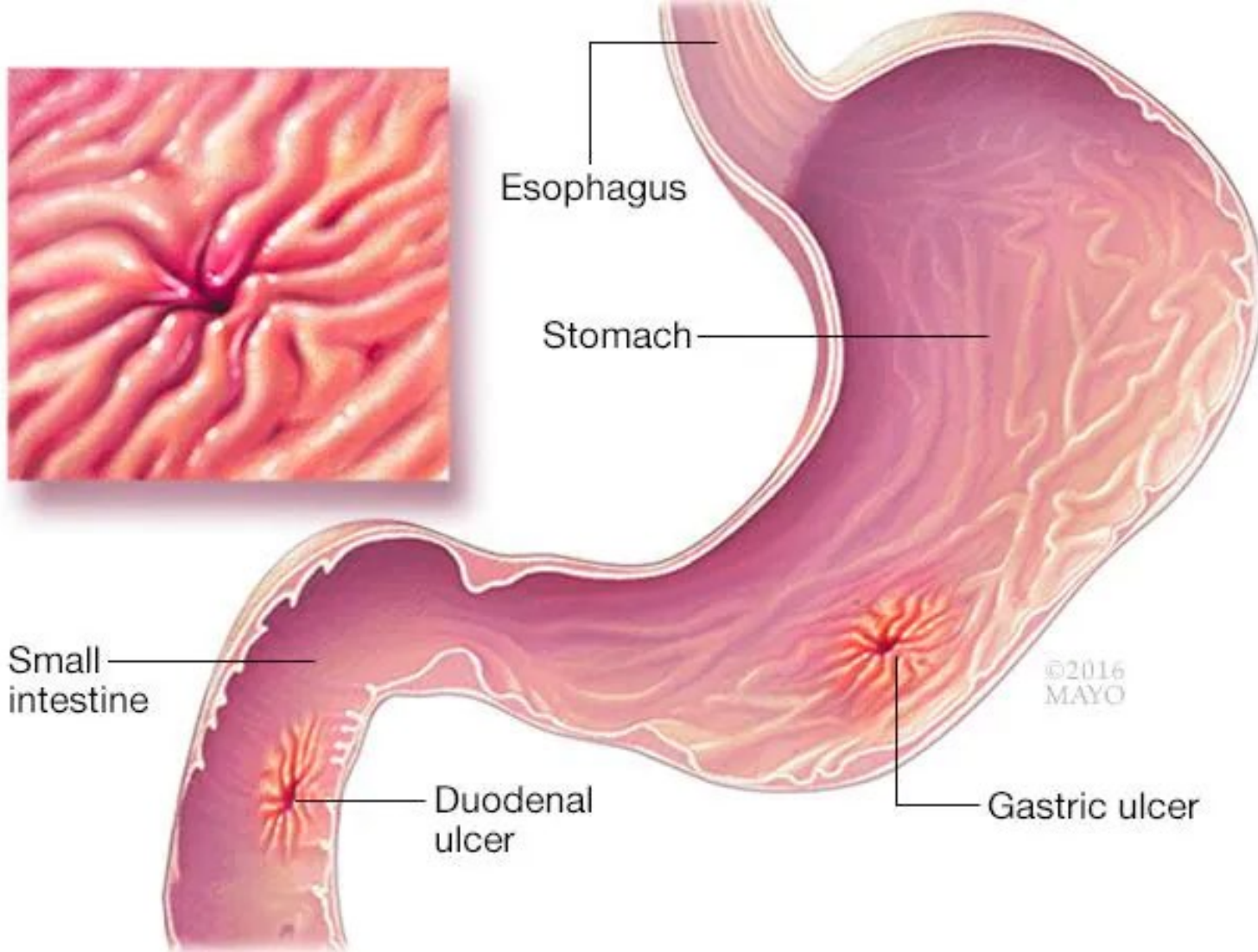
(a) Normal



(b) Peptic ulcer

**Gastritis**, inflammation of the stomach, can lead to a **peptic ulcer** as pepsin and hydrochloric acid erode the stomach wall

Most ulcers are caused by acid-resistant bacteria, ***Helicobacter pylori*** that can be treated with antibiotics and Pepto-Bismol.



Helicobacter pylori (*H. pylori*) is a type of bacteria that infects the stomach and is a common cause of peptic ulcers and gastritis. While many people with *H. pylori* infection don't experience symptoms, it can cause ulcers and may increase the risk of stomach cancer.

# Gastric Motility

---

Antrum of the stomach holds about 30 ml of chyme

As a parastaltic wave passes down the antrum, it moves about **3 mL of chyme** into the duodenum with each contraction

Allows only a small amount of chyme into the duodenum /// enables the duodenum to

- neutralize the stomach acid
- digest nutrients more efficiently

If duodenum is over filled then it inhibits gastric motility

**Typical meal emptied from stomach in 4 hours**

- less time if the meal is more liquid
- as long **as 6 hours for a high fat meal**

# Digestion and Absorption Functions of the Stomach

---

Most chemical digestion (99%+) and nearly all absorption occur after the chyme has passed into the small intestine

Salivary and gastric enzymes partially digest protein and lesser amounts of starch and fat in the stomach

Stomach does not absorb any significant amount of nutrients

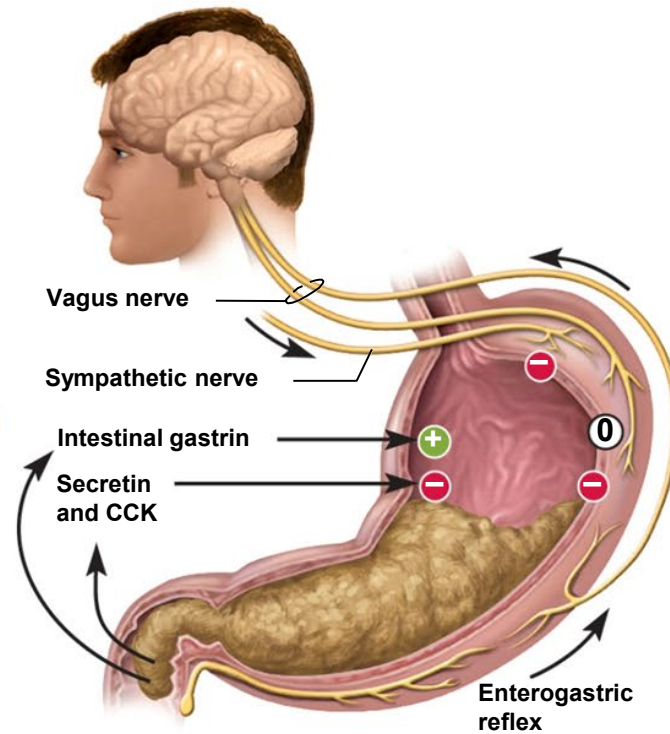
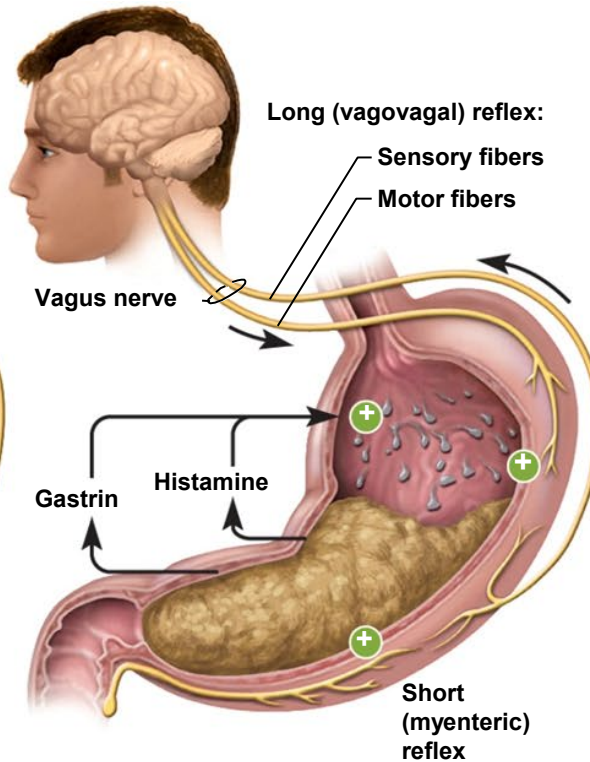
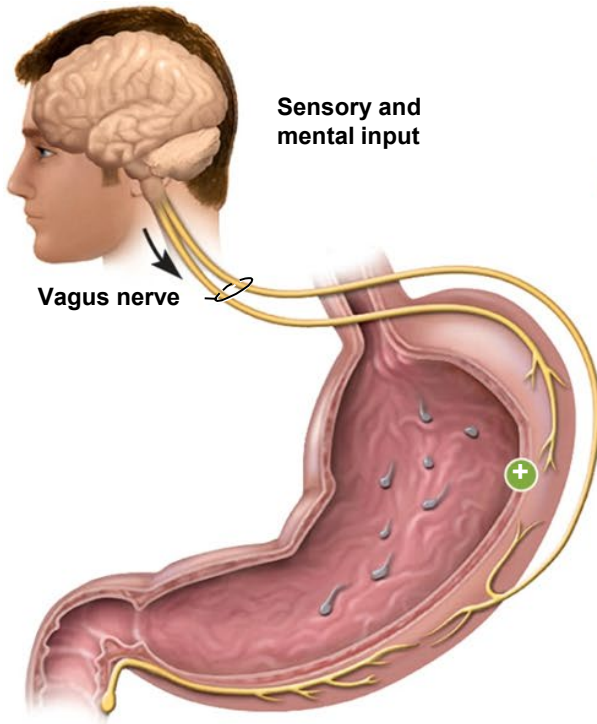
- Stomach does absorb **aspirin and some lipid-soluble drugs**

Alcohol is absorbed mainly by small intestine // intoxicating effects depends partly on how rapidly the stomach is emptied

Note: stomach detoxifies about 20% of alcohol before it enters small intestine

# Regulation of the Stomach

## Cephalic vs Gastric vs Intestinal



- 1 Cephalic phase**  
Vagus nerve stimulates gastric secretion even before food is swallowed.

- 2 Gastric phase**  
Food stretches the stomach and activates myenteric and vagovagal reflexes. These reflexes stimulate gastric secretion. Histamine and gastrin also stimulate acid and enzyme

- 3 Intestinal phase**  
Intestinal gastrin briefly stimulates the stomach, but then secretin, CCK, and the enterogastric reflex inhibit gastric secretion and motility while the duodenum processes the chyme already in it. Sympathetic nerve fibers suppress gastric activity, while vagal (parasympathetic) stimulation of the stomach is now inhibited.

### Key

- + Stimulation
- Inhibition
- 0 Reduced or no effect

# Cephalic Phase Regulation

---

**First Phase = cephalic phase**

**stomach responds** to site, smell, taste, or thought of food

sensory and mental inputs converge on the **hypothalamus** // relays signals to **medulla oblongata**

**vagus nerve** fibers from medulla oblongata stimulate the **enteric nervous system** of stomach // this then stimulates gastric secretion

# Gastric Phase Regulation

---

## **Second Phase = gastric phase**

period in which swallowed food and semi-digested protein in stomach activates gastric activity /// **two-thirds of gastric secretion** occurs in this phase

**ingested food stimulates gastric activity in two ways:**

- by **stretching the stomach // this** activates **short reflex** mediated through **myenteric nerve plexus** and **long reflex** mediated through the **vagus nerves signals to the brainstem**
- by **increasing the pH** of its contents

# Gastric Phase Regulation

---

## More on Second Phase

**gastric secretion is stimulated by three chemicals**

**acetylcholine (ACh)** – secreted by parasympathetic nerve fibers

**histamine** – a paracrine secretion from enteroendocrine cells in the gastric glands

**gastrin** – a hormone produced by the enteroendocrine cells (i.e. **G cells**) in pyloric glands

# Intestinal Phase Regulation

---

## Third Phase = intestinal phase

stage in which the duodenum responds to arriving chyme and moderates gastric activity through hormones and nervous reflexes

duodenum **initially enhances gastric secretions** // stretching of the duodenum accentuates vagovagal reflex that stimulates the stomach

peptides and amino acids in chyme stimulate **G cells** in the duodenum to secrete more **gastrin** which further stimulates the stomach

but then the **intestinal phase inhibits gastric secretion** by the **enterogastric reflex** // see next slide

# Intestinal Phase Regulation

---

## The Enterogastric Reflex

duodenum sends **inhibitory signals** to the stomach by way of the **enteric nervous system**

pyloric sphincter contracts tightly to limit chyme entering duodenum // gives duodenum time to process chyme

**enteroendocrine cells** also participate in this reflex (see next slide)

at same time signals also sent to the medulla oblongata - triggered by acid and semi-digested fats in the duodenum

» **inhibits vagal nuclei** – reducing vagal stimulation of the stomach

» **stimulate sympathetic neurons** – send inhibitory signals to the stomach

# Regulation of Gastric Function – Enterogastric Reflex

---

Chyme also stimulates duodenal **enteroendocrine cells** to release these hormones:

- > **Secretin**
- > **Cholecystokinin**
- > **Glucose dependent insulinotropic peptide (GDIP)**
- > **Glucagon like peptide-1 (GLP-1)**

Secretin and cholecystokinin stimulate secretions from the pancreas and gall bladder

During intestinal phase secretin and cholecystokinin inhibit gastric secretions

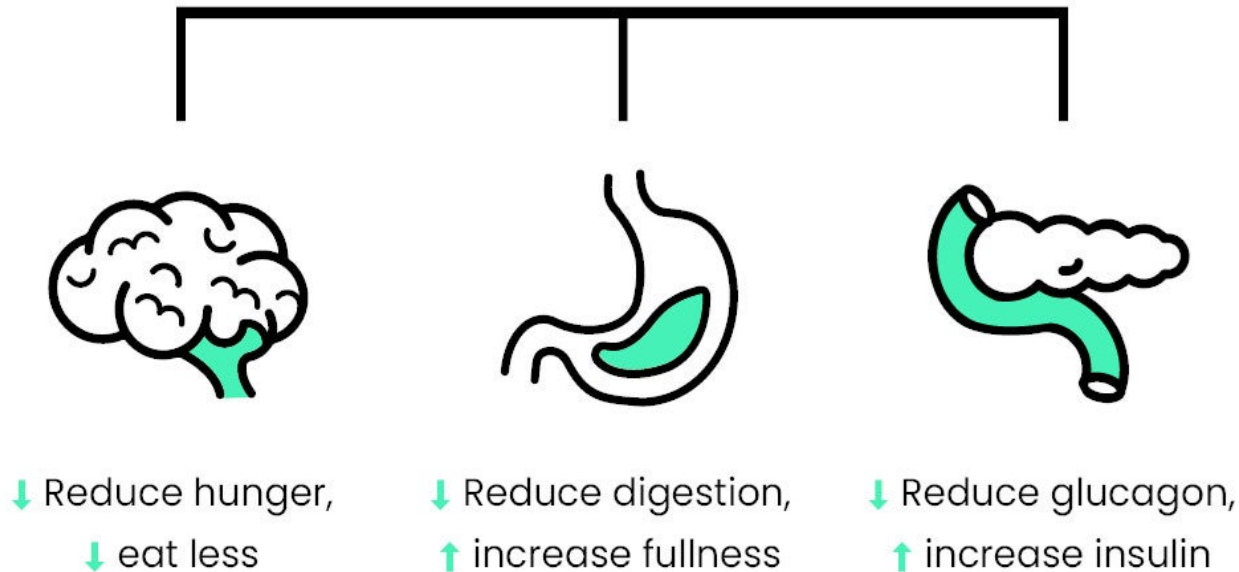
GDIP inhibit gastric secretions but stimulate insulin secretion by pancreas in preparation for processing nutrients about into small intestine // responsible for 70% of insulin release after eating

*Note: glucagon like peptide-1 (GLP-1) is the newly approved weight loss drug sold under many different type of names. (See Next Slide)*

Some examples of GLP-1-mimicking drugs include: Semaglutide: A synthetic drug that mimics GLP-1 // Ozempic: An injectable drug that mimics GLP-1 // Orforglipron: An oral drug that mimics GLP-1

These drugs are only approved for certain people, such as those with obesity or type 2 diabetes. Some side effects of these drugs include nausea, diarrhea, constipation, and increased risk of gut-related side effects.

## GLP-1



(More to come on this topic in C26)

# Microscopic Anatomy of the Stomach

---

**Simple columnar epithelium** covers mucosa

apical regions of stomach's surface cells are filled with **mucin** // swells with water and becomes **mucus** after it is secreted

mucosa and submucosa flat when stomach is full, but form longitudinal wrinkles called **gastric rugae** when empty

**muscularis externa** has three layers instead of two /// outer longitudinal, middle circular and inner oblique layers

**gastric pits** – depressions in gastric mucosa

– lined with simple columnar epithelium // two or three tubular glands open into the bottom of each gastric pit

–**cardiac glands** in cardiac region

–**pyloric glands** in pyloric regions

–**gastric glands** in the rest of the stomach

# Cells of Gastric Glands

**Regenerative (stem) cells** – found in the base of the pit and in the neck of the gland

divide rapidly and produce a continual supply of new cells to replace cells that die

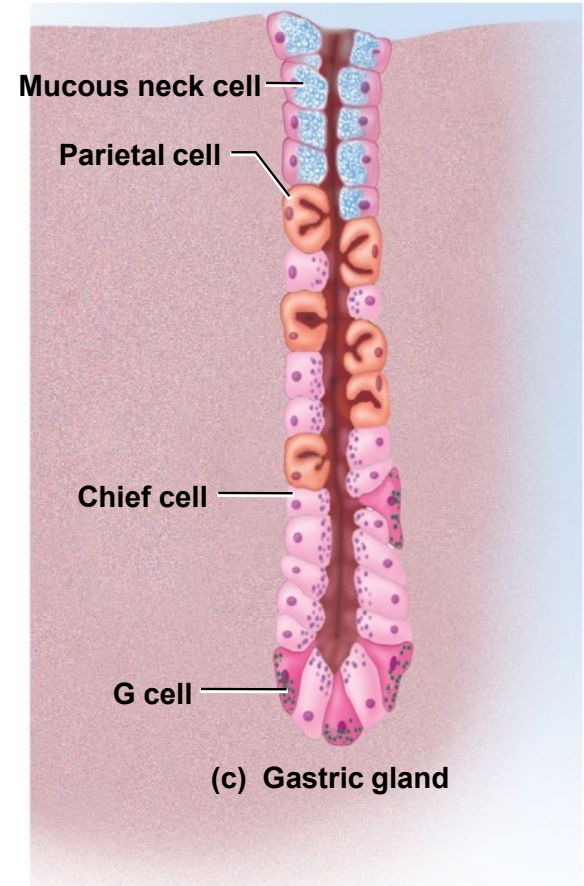
**Mucous cells** – secrete mucus // predominate in cardiac and pyloric glands in gastric glands, called **mucous neck cells** since they are concentrated at the neck of the gland

**Parietal cells** – found mostly in the upper half of the gland // produce these secretions

- hydrochloric acid (HCl)

- intrinsic factor

- ghrelin / hunger hormone / stomach empty sends signal to hypothalamus – go find food!



**Chief cells** – most numerous

secrete **gastric lipase** and **pepsinogen**

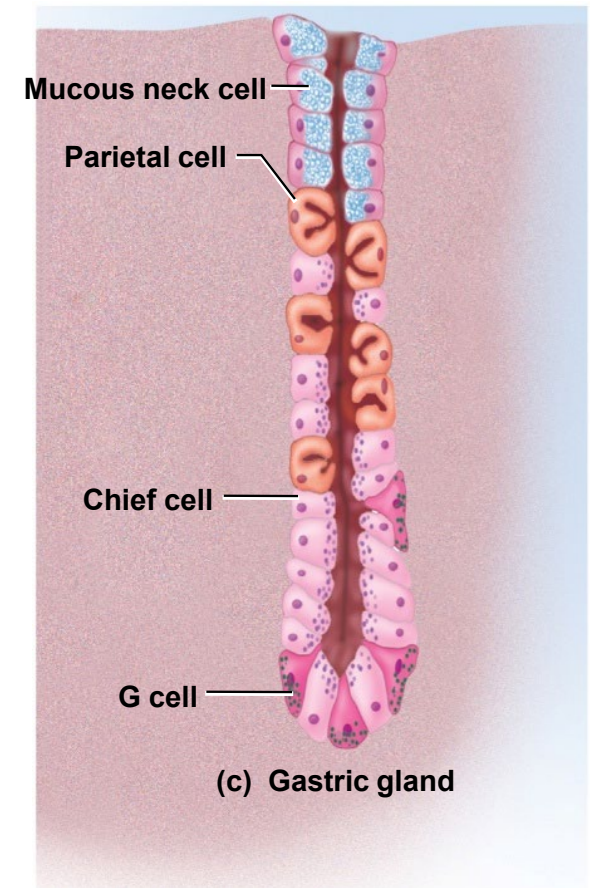
dominate lower half of gastric glands

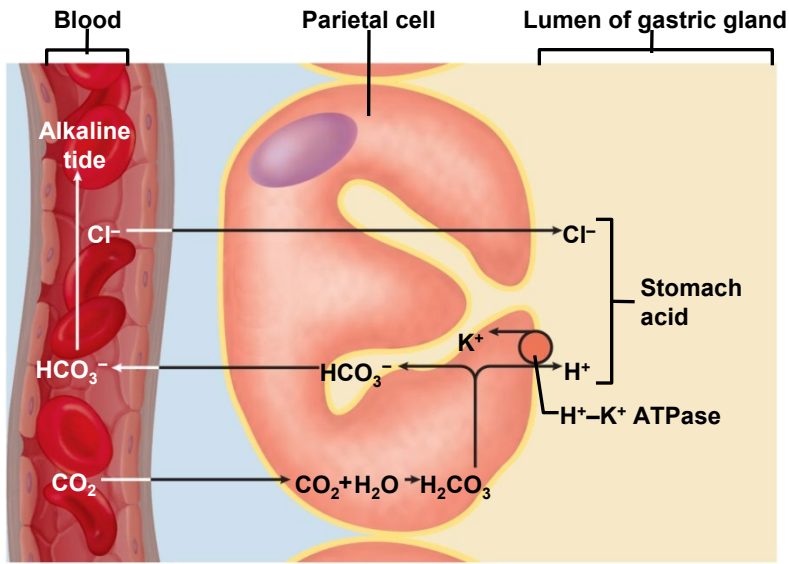
absent in pyloric and cardiac glands

**What are the enteroendocrine cells of the gastric pit?**

- concentrated in lower end of gland
- consist of up to eight different cell lines (e.g. G cell = gastrin)
- secrete **hormones** and **paracrine messengers** that regulate digestion

## Cells of Gastric Glands





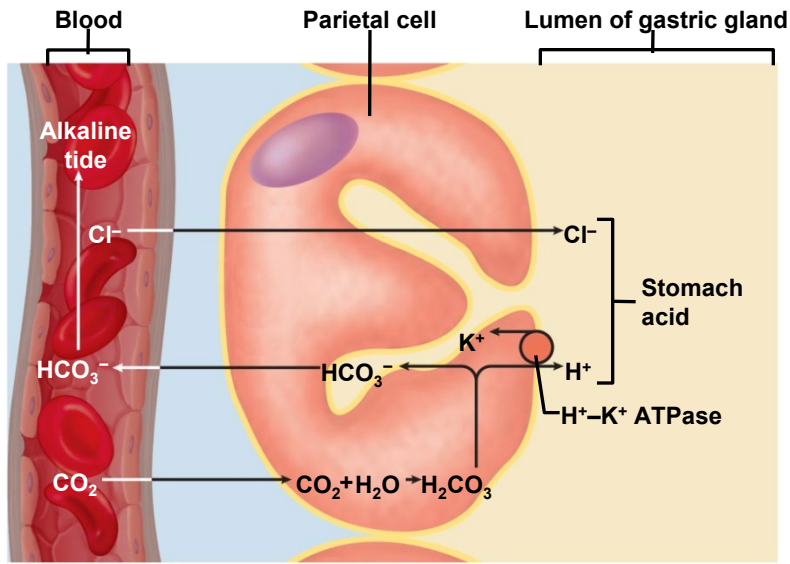
## How is stomach acid made?

**Gastric juice** has a high concentration of **hydrochloric acid** // pH as low as 0.8

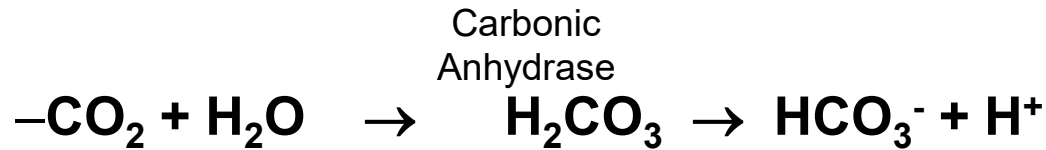
**Parietal cells produce HCl** (use carbonic anhydrase (CAH) to make HCl)

What is an acid? How do we make free protons?

- See Next Slide



# Hydrochloric Acid



– $\text{H}^+$  is pumped into gastric gland's lumen by the antiport,  $\text{H}^+ - \text{K}^+$  ATPase pump // antiporter uses ATP to pump  $\text{H}^+$  out and  $\text{K}^+$  in

– $\text{HCO}_3^-$  exchanged for  $\text{Cl}^-$  (**chloride shift**) from blood plasma

• $\text{Cl}^-$  (chloride ion) pumped into the lumen of gastric gland to join  $\text{H}^+$  forming **HCl**

•elevated  $\text{HCO}_3^-$  (bicarbonate ion) in blood causes **alkaline tide** increasing blood pH

# Functions of Hydrochloric Acid

---

Activates **pepsin** and **lingual lipase**

Breaks up connective tissues and plant cell walls // helps liquefy food to form **chyme**

Converts ingested **ferric ions ( $\text{Fe}^{3+}$ )** to **ferrous ions ( $\text{Fe}^{2+}$ )** //  $\text{Fe}^{2+}$  absorbed and used for hemoglobin synthesis

Contributes to nonspecific disease resistance by **destroying most ingested pathogens**

# Pepsin

---

**Zymogens are** digestive enzymes secreted as inactive proteins /// converted to active enzymes by removing some of their amino acids

**Pepsinogen** is a zymogen secreted by the chief cells /// HCl converts pepsinogen into pepsin after enzyme is inside stomach

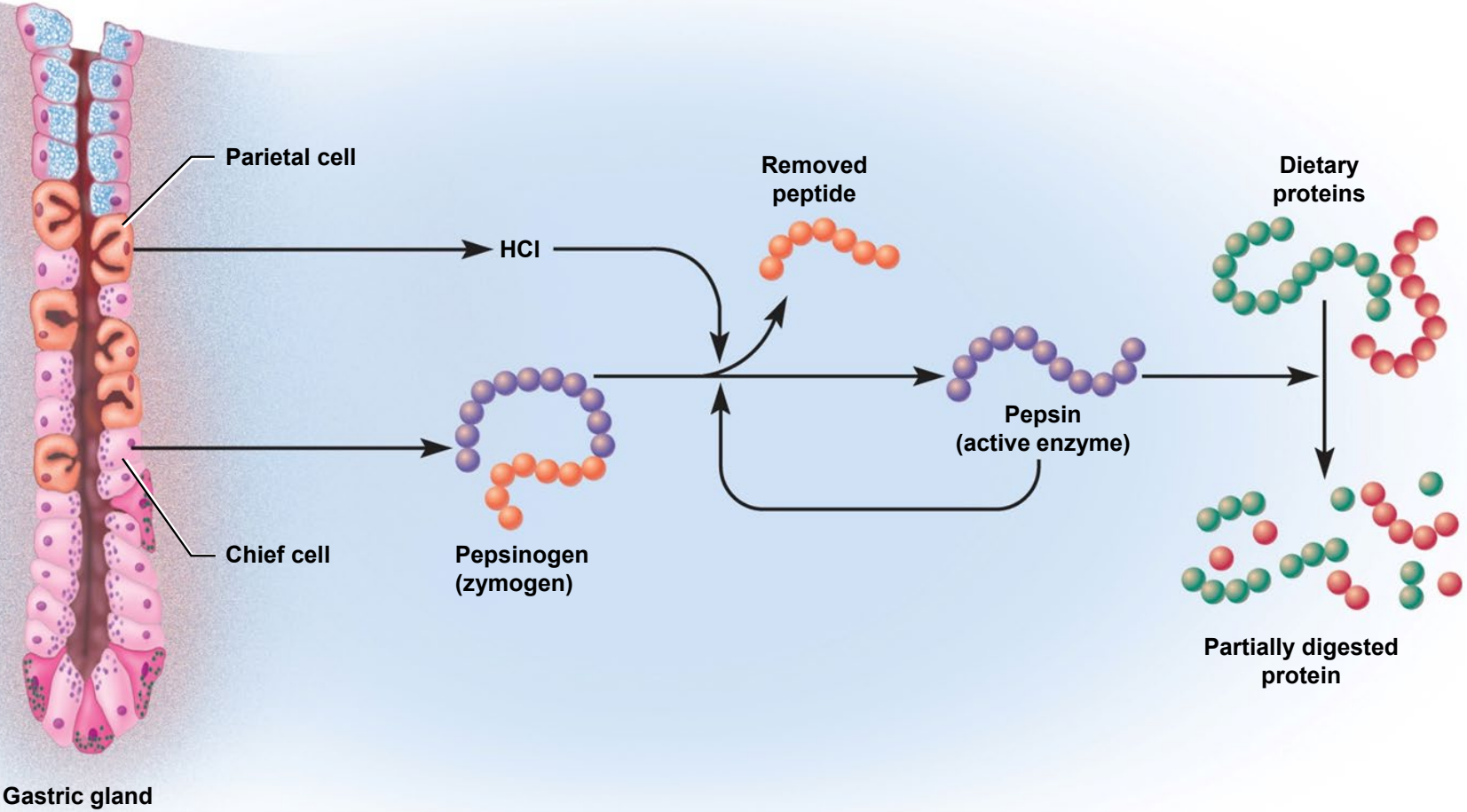
hydrochloric acid removes some of its amino acids to form pepsin

**Autocatalytic effect** – as pepsin is formed, now pepsin converts more pepsinogen into more pepsin // **positive feedback mechanism**

Pepsin digests dietary proteins into shorter peptide chains

Note: protein digestion starts in stomach and is completed in the small intestine

# Production and Action of Pepsin



# Gastric Lipase

---

Produced by **chief cells**

Important for infants (not produced in adults)

**Gastric lipase** and **lingual lipase** play a **minor role in digesting dietary fats** // lingual lipase digests only 15% of dietary fats in the stomach

Pancreatic lipase accounts for 85% of fats digested in the small intestine

# Intrinsic Factor

---

Intrinsic factor is a glycoprotein secreted by **parietal cells**

Intrinsic factor is essential for the **absorption of vitamin B<sub>12</sub>** by the small intestine

Binds vitamin B<sub>12</sub> and intestinal cells absorb this complex by receptor-mediated endocytosis

Vitamin B<sub>12</sub> is needed to synthesize hemoglobin // required to prevent **pernicious anemia**

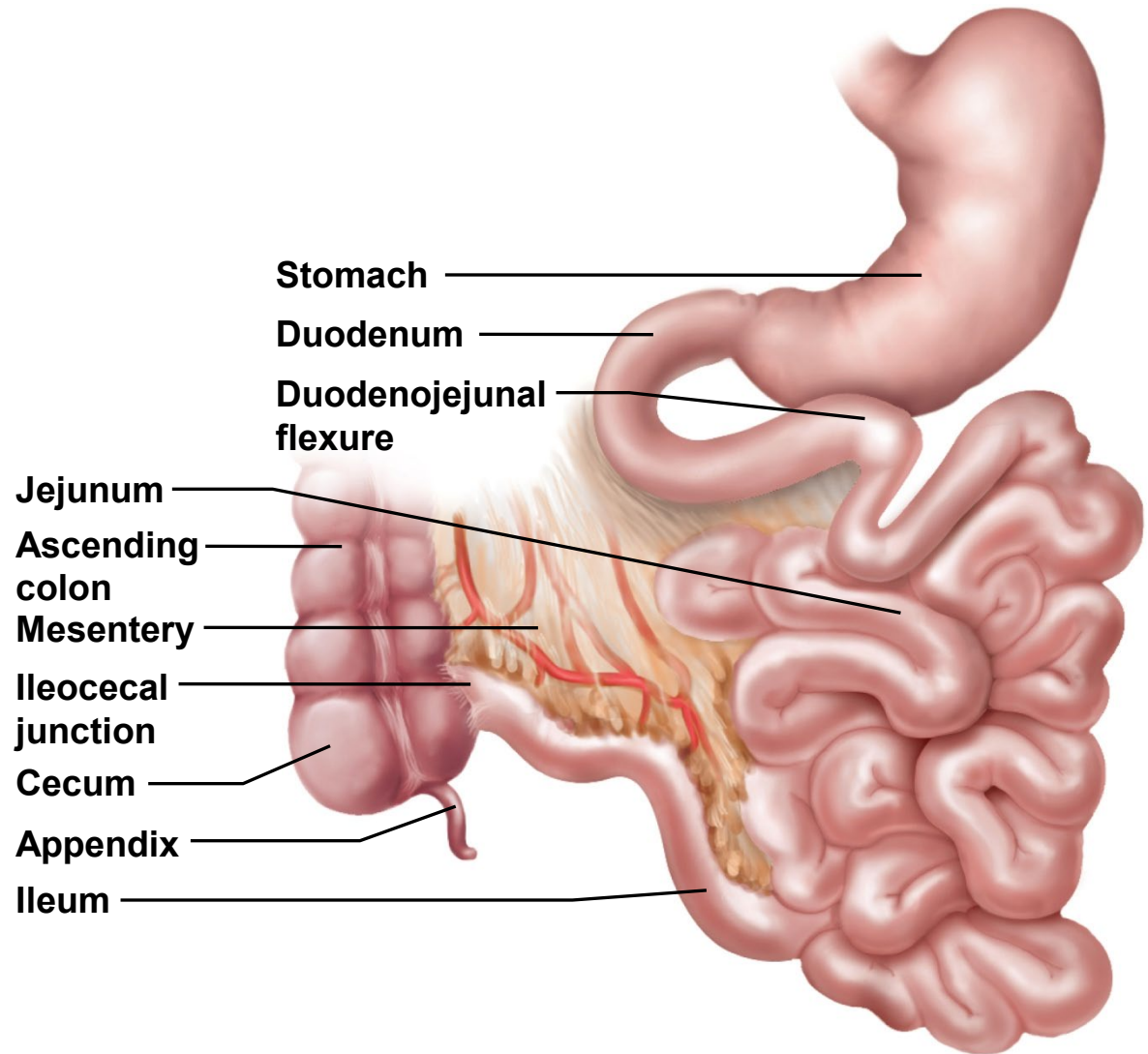
Secretion of intrinsic factor is the only indispensable function of the stomach

Digestion continues if stomach is removed (gastrectomy), but B<sub>12</sub> supplements will be needed

# Small Intestine

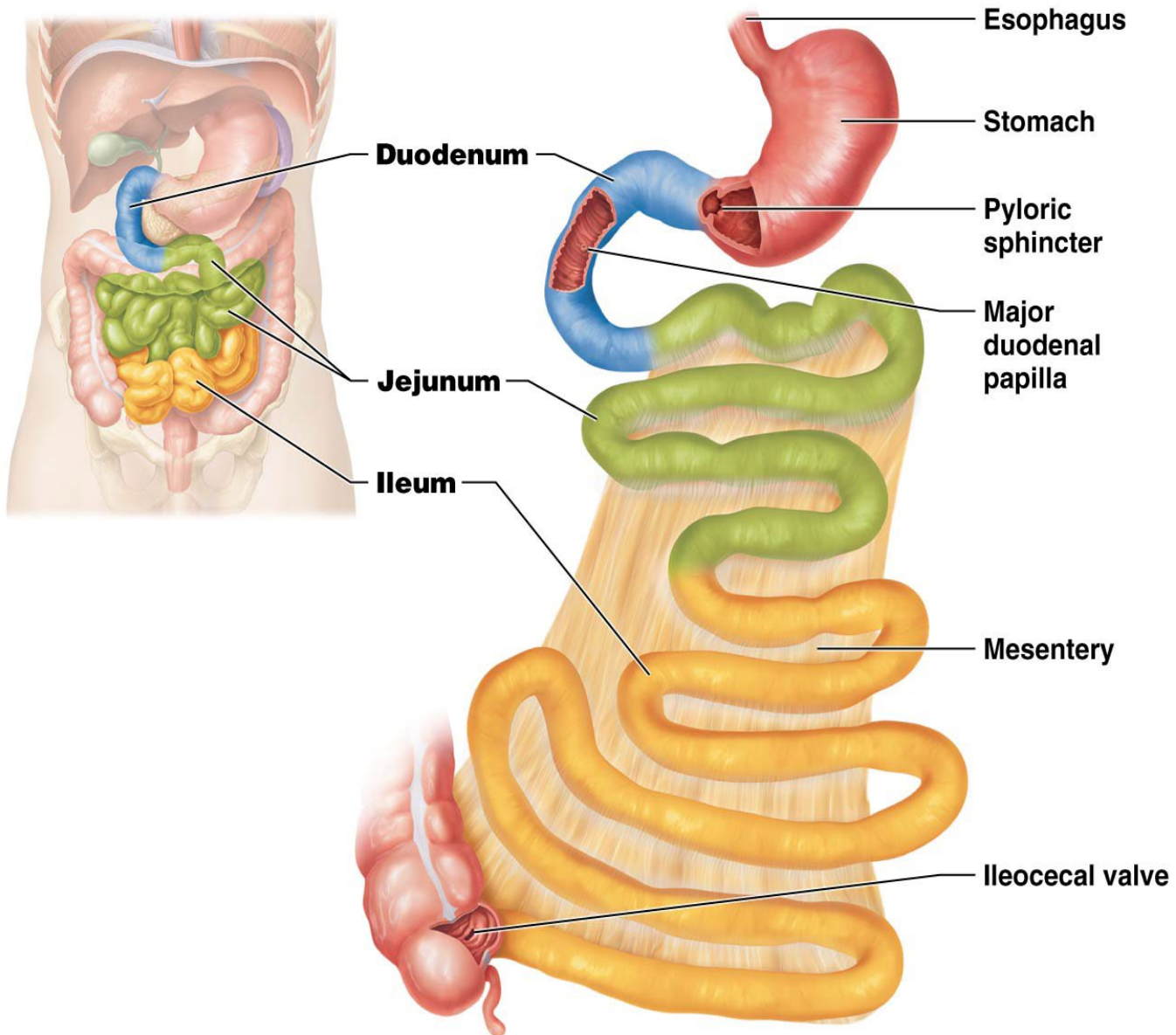
Small intestine about 24 ft  
Duodenum first 10 inches

Jejunum 40%  
Ileum 60%



Coiled mass filling most of the abdominal cavity inferior to the stomach and the liver

# Small Intestine



# Small Intestine

---

Nearly all chemical digestion and nutrient absorption occurs in small intestine (99%)

The longest segment of the digestive tract

2.7 to 4.5 m long in a living person

4 to 8 m long in a cadaver where there is no muscle tone

Small refers to the diameter not its length //  
diameter = 2.5 cm (1 inch)

# Duodenum

---

## Duodenum

the first 25 cm (10 inches)

begins at the **pyloric valve**

**major and minor duodenal papilla** distal to pyloric valve // receives **major and minor pancreatic ducts** respectively

arches around the **head of the pancreas**

ends at a sharp bend called the **duodenojejunal flexure**

most is **retroperitoneal**

# Secretions into the Duodenum

---

**Duodenal glands** – in submucosa of duodenum

secrete an abundance of **bicarbonate-rich mucus**

neutralizes stomach acid and shields the mucosa from its erosive effects

Note: large population of **defensive lymphocytes** throughout lamina propria and submucosa of small intestine

*Do you remember the function of the “M cells”?*

# Jejunum

---

## Jejunum

40% of small intestine beyond duodenum

roughly 1.0 to 1.7 m in a living person

has large, tall, closely spaced circular folds

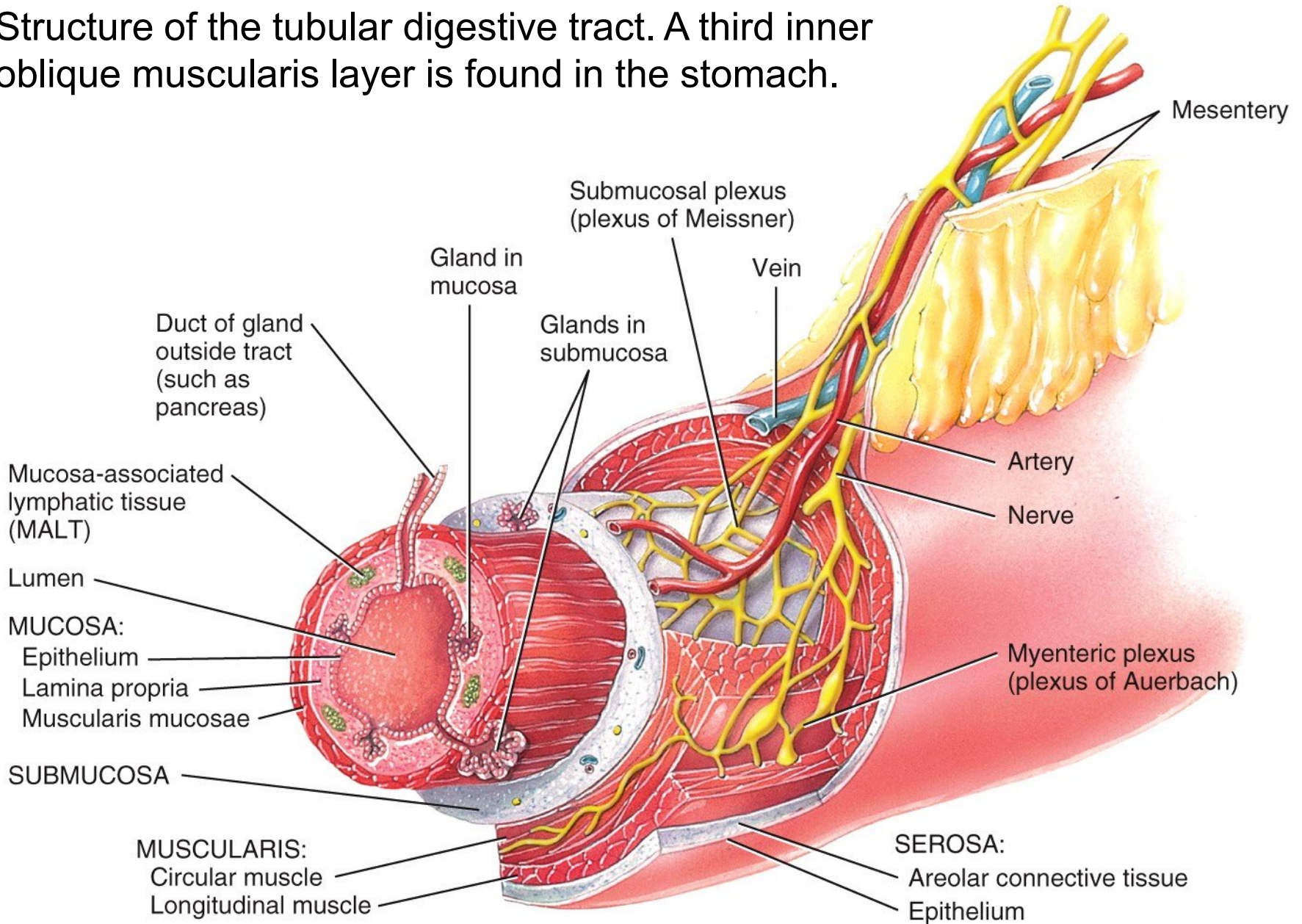
its wall is relatively thick and muscular

especially rich blood supply which gives it a red color

most digestion and nutrient absorption occurs here

jejunum means empty

Structure of the tubular digestive tract. A third inner oblique muscularis layer is found in the stomach.



# Intestinal Motility

---

Contractions of small intestine serve three functions:

to **mix chyme** with intestinal juice, bile, and pancreatic juice to neutralize acid

digest nutrients more effectively // to **bring chyme in contact with the mucosa** for contact digestion and nutrient absorption

to **move residue** toward large intestine

# Control of Motility and Secretion In the Small Intestine

---

## Neural control

short (myenteric) reflexes – stretch or chemical stimulation acts through myenteric plexus // stimulates parastaltic contractions of swallowing

long (vagovagal) reflexes - parasympathetic stimulation of digestive motility and secretion

## Hormones

chemical messengers secreted into bloodstream, and stimulate distant parts of the digestive tract

enteroendocrines: Gastrin, secretin, and cholecystokinin (CCK),

## Paracrine secretions

chemical messengers that diffuse through the tissue fluids to stimulate nearby target cells



# Intestinal Motility

## Segmentation VS Peristalsis

---

**Segmentation** – the movement in which stationary ringlike constrictions appear in several places along the intestine // this is designed not to advance chyme but to mix chyme with pancreatic enzymes and bring nutrients into contact with brush boarder enzymes

they relax and new constrictions form elsewhere  
most common kind of intestinal contraction  
pacemaker cells in muscularis externa set rhythm of Segmentation

contractions about 12 times per minute in the duodenum // 8 to 9 times per minute in the ileum

after most nutrients have been absorbed and little remains but undigested residue, segmentation declines and peristalsis begins

# Peristalsis

## Also Called the Migrating Motor Complex

---

Causes gradual movement of contents towards colon


**Peristaltic wave** begins in the duodenum, travels 10 to 70 cm and dies out /// followed by another wave starting further down the tract

**Migrating motor complex** – successive, overlapping waves of contraction /// milk chyme toward colon over a period of two hours

**The ileocecal valve** usually closed but food in stomach triggers **gastroileal reflex** that enhances segmentation in the ileum and relaxes the valve

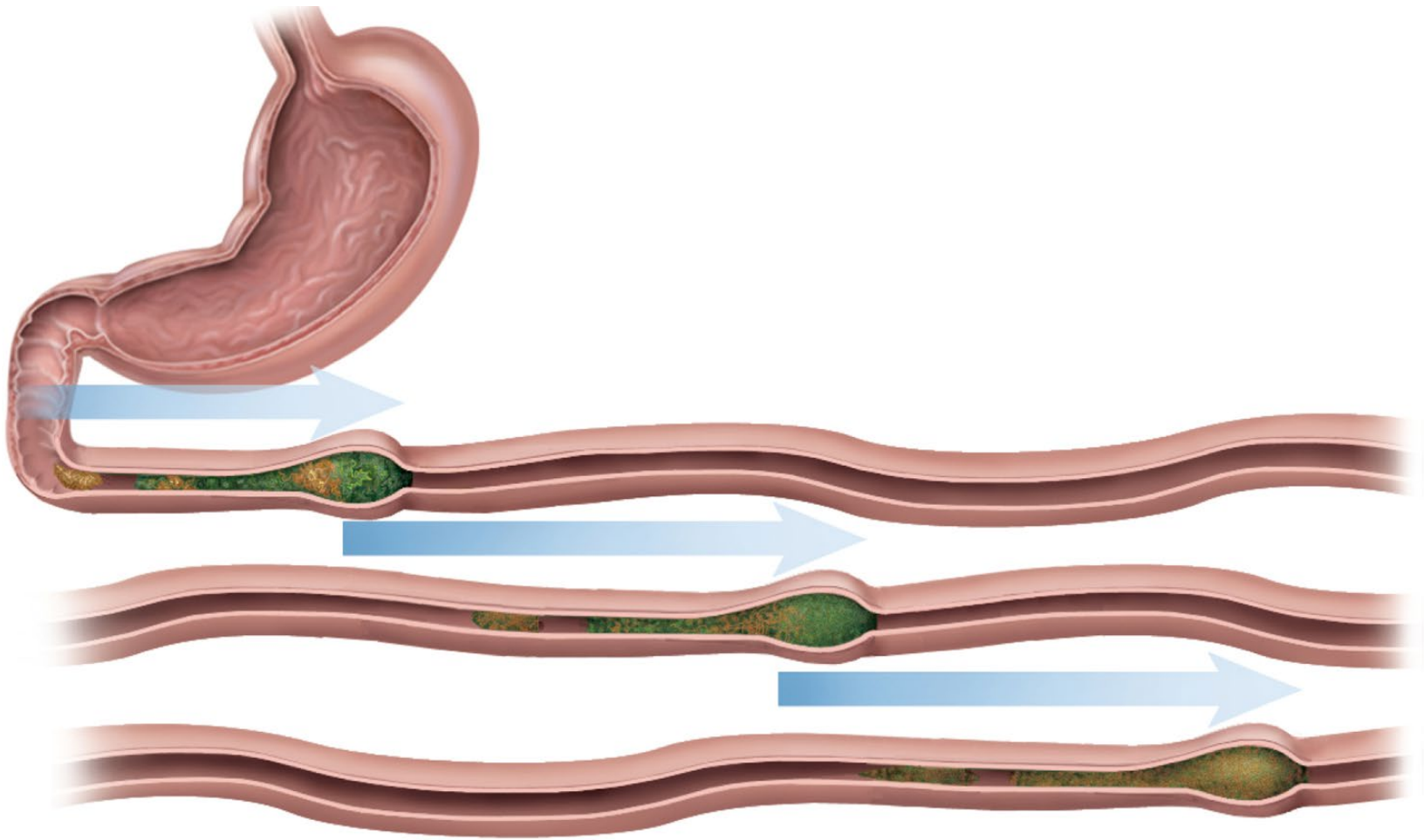
As **cecum** fills with residue, pressure pinches the valve shut /// prevents reflux of cecal contents into the ileum

# Segmentation in Small Intestine



**(a) Segmentation**

purpose of segmentation is to mix and churn  
not to move material along as in peristalsis



**(b) Peristalsis** : purpose to advance chyme towards large intestine

# How is the surface area in small intestine increased?

---

**Need large internal surface area** for effective digestion and absorption

Tissue layers have **modifications for nutrient digestion and absorption** // lumen lined with **simple columnar epithelium**

greater length and **three types of internal folds** or projections

**circular folds (plicae circulares)** – increase surface area by a factor of 2 to 3

**villi** – increase surface area by a factor of 10

**microvilli** – increase the surface area by a factor of 20 // 1,700 per cell

# How is the surface area in small intestine increased?

---

## **Circular folds** (plicae circulares)

- largest folds of intestinal wall // up to 10 mm high
- involve only mucosa and submucosa
- occur from the duodenum to the middle of the ileum
- cause chyme flow in spiral path causing more contact with mucosa
- promotes more thorough mixing and nutrient absorption
- relatively small and sparse in ileum and not found in distal half // most nutrient absorption is completed by this point

# How is the surface area in small intestine increased?

---

## Villi

fingerlike projections 0.5 to 1 mm tall // make mucosa look fuzzy

villus covered with two types of epithelial cells

**absorptive cells (enterocytes)**

**goblet cells** – secrete mucus

epithelium joined by tight junctions that prevent digestive enzymes from seeping between them

# How is the surface area in small intestine increased?

---

## Villi

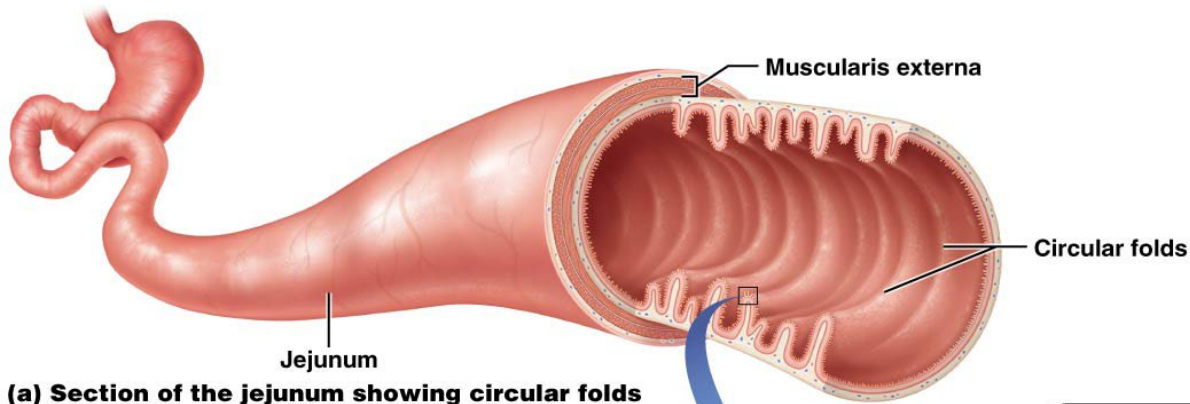
core of villus filled with areolar tissue of the lamina propria

embedded in this tissue are an arteriole, a capillary network, a venule, and a lymphatic capillary called a lacteal

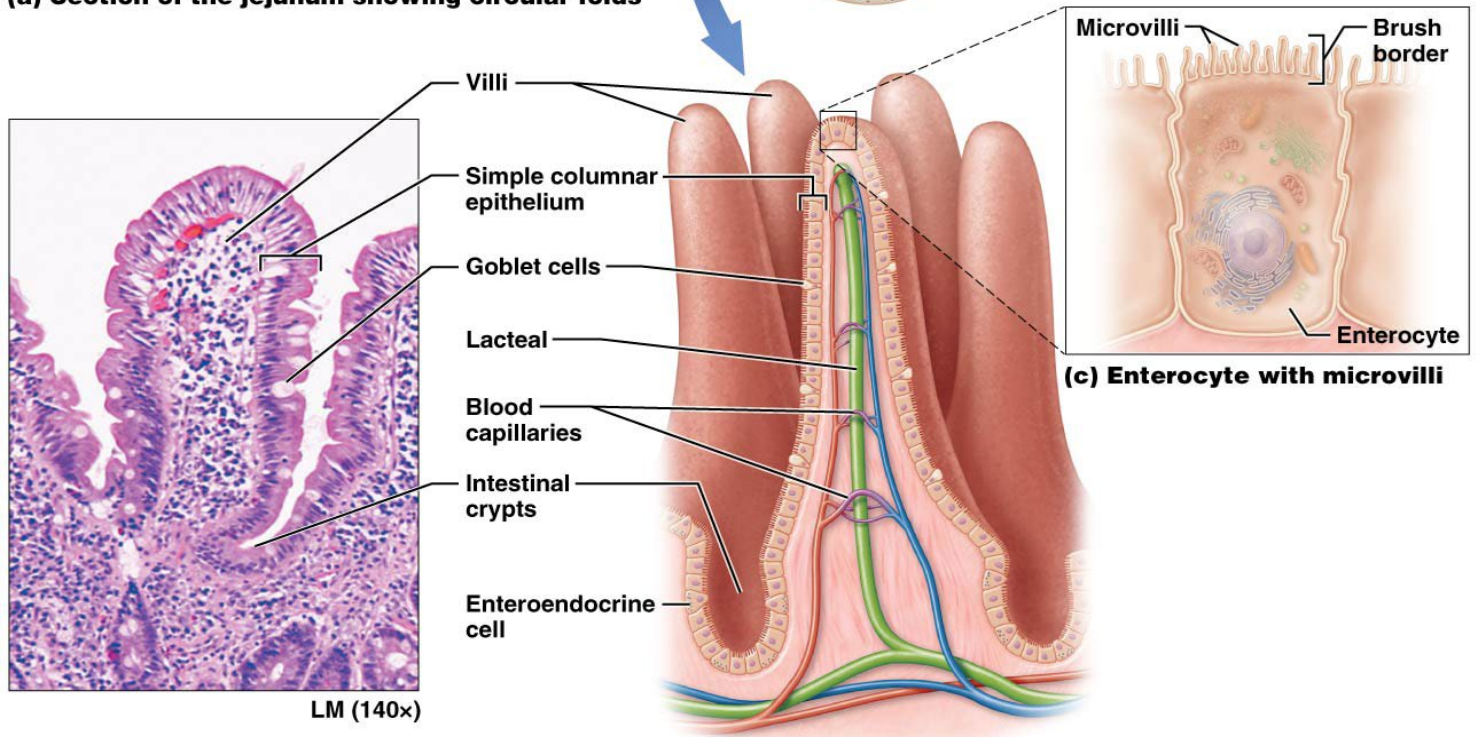
blood capillaries of villus absorb most of the nutrients

lacteal absorbs most lipids

# Why is it important to increase the surface area in the small intestines?

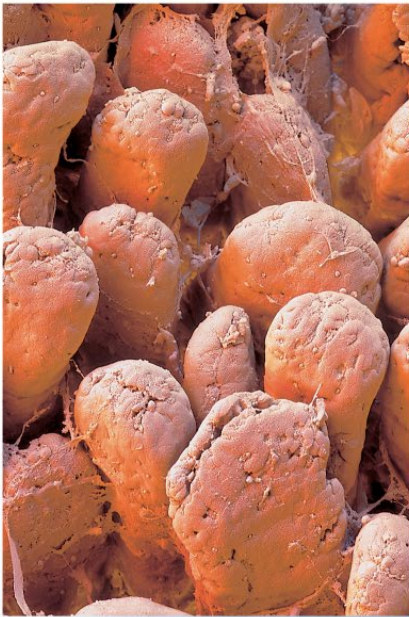

**(a) Section of the jejunum showing circular folds**

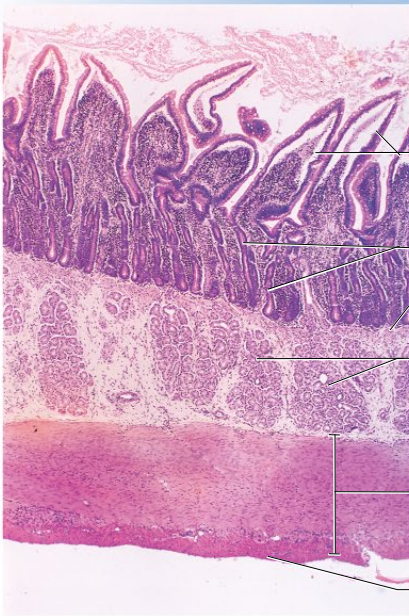


**(b) Intestinal villi, photomicrograph (left) and illustration (right)**

**(c) Enterocyte with microvilli**



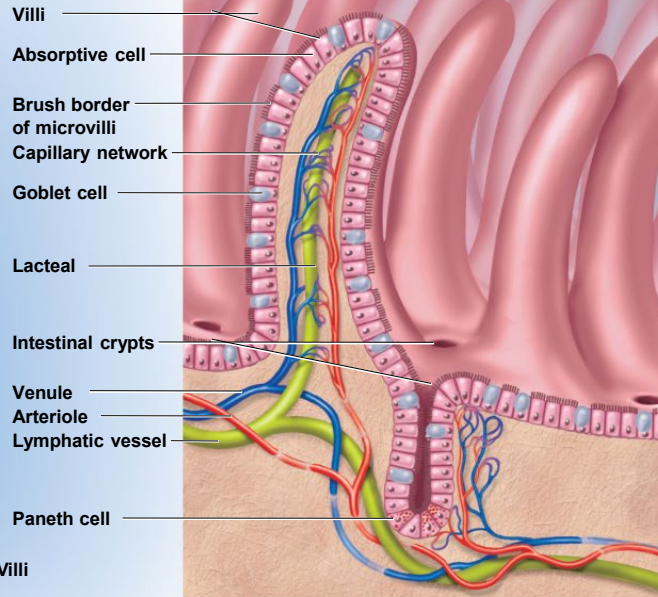
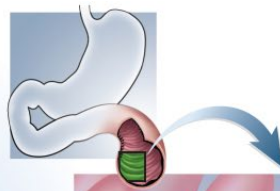(a)



(b)

0.5 mm

- Villi
- Intestinal crypts
- Muscularis mucosae
- Duodenal glands
- Muscularis externa
- Serosa

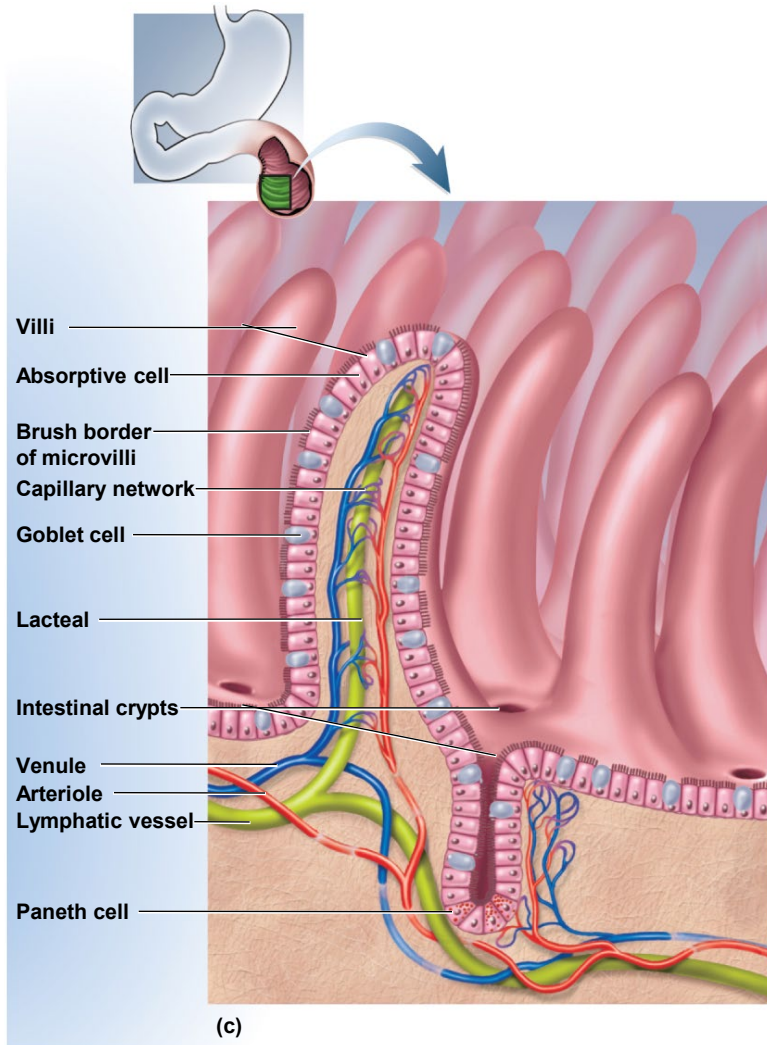


(c)

The cells covering the villi are simple columnar epithelial cells with microvilli. These cells are supported by a basement membrane and beneath the basement membrane is the propria lamina. In the core of the villi are fenestrated capillaries and a lacteal.

What type of nutrients are absorbed by the fenestrated capillaries and the lacteals?

# Microscopic Anatomy



**Microvilli** – fuzzy border of microvilli on apical surface of each absorptive cell

- about 1  $\mu\text{m}$  high
- blood capillaries of villus absorb hydrophilic nutrients
- lacteal absorbs most hydrophobic (lipids) packaged into chylomicrons
- the **brush border** increases absorptive surface area
- **brush border enzymes** – contained in the plasma membrane of epithelial cells with microvilli
- brush border enzymes carry out some of the final stages of enzymatic digestion // **contact digestion** – the chyme must contact the brush border for digestion to occur
- intestinal churning of chyme insures contact with the mucosa

# Microscopic Anatomy

## Microvilli

fuzzy border of microvilli on apical surface of each absorptive cell

about 1  $\mu\text{m}$  high

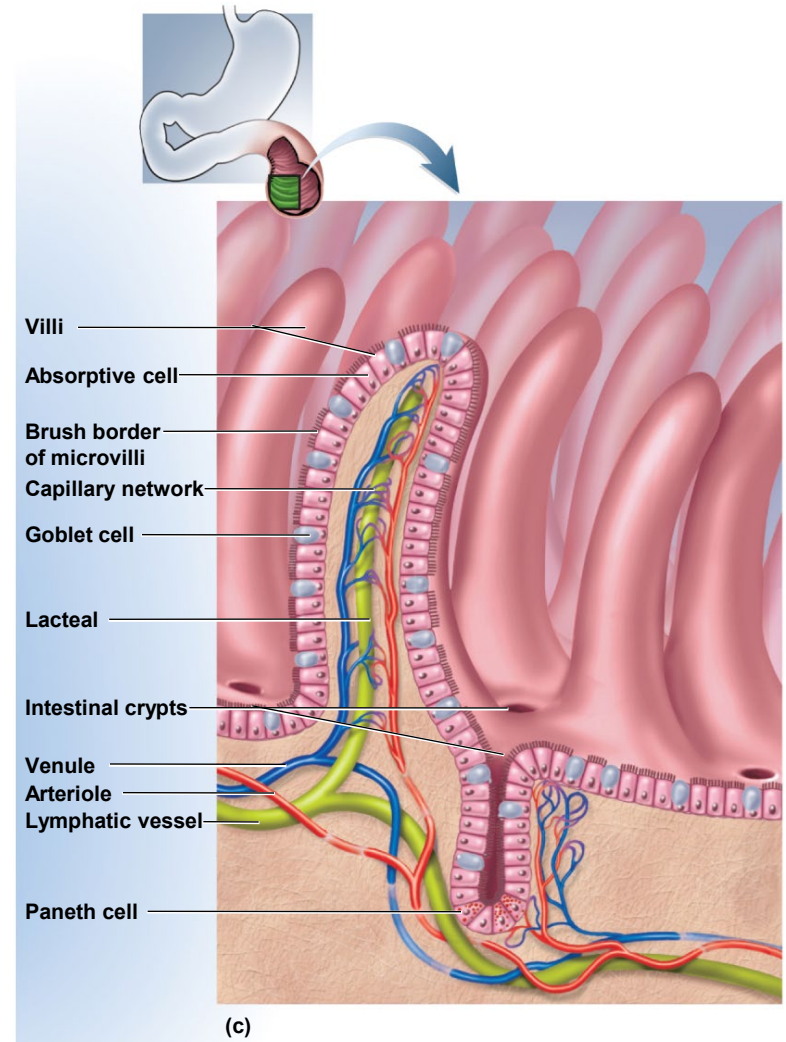
the brush border increases absorptive surface area

**brush border enzymes** – contained in the plasma membrane of microvilli

carry out some of the final stages of enzymatic digestion

not released into the lumen

**contact digestion** – the chyme must contact the brush border for digestion to occur /// intestinal churning of chyme insures contact with the mucosa



# Intestinal Crypts (Crypts of Lieberkühn)

---

These are numerous pores that open into tubular glands on the floor of the small intestine **between the bases of the villi**

like gastric glands

in upper half, have **enterocytes** and **goblet** cells like the villi

in lower half, dominated by dividing **stem cells**

life span of **3 to 6 days** // new epithelial cells migrate up the crypt to the tip of the villus where it is sloughed off and digested

a few **Paneth Cells** are clustered at the base of each crypt ///  
secrete **lysozyme, phospholipase, and defensins** (defensive proteins that resist bacterial invasion of the mucosa)

# Ileum

---

Forms the **last 60%** of the post duodenal small intestine

about 1.6 to 2.7 m

thinner, less muscular, less vascular, and paler pink color

**ileocecal junction** - the end of the small intestine where the **ileum** joins the **cecum** of the large intestine

**ileocecal valve** - not a true sphincter muscle but formed by the thickened muscularis of the ileum

protrudes into the cecum // regulates passage of food residue into the large intestine

# Ilium - Distal End of Small Intestine

---

Both jejunum and ileum are **intraperitoneal** and covered with **serosa**

**Peyer patches** – prominent lymphatic nodules in clusters on the side opposite the mesenteric attachment

- readily visible with the naked eye
- become progressively larger approaching the large intestine


# M Cells on Peyer's Patches in the Ileum

This is how immune cells try to find out (i.e. recognize) what type of pathogens may “break into” the sterile compartments of your body.

Immune cells recognize bacteria inside the lumen of the ileum before they cross the mucosa

Immune cells make antibodies and memory cell. The antibodies are Sig-A (secretory IgA) secreted into the lumen of the ileum. The antibodies render the bacteria “harmless”.

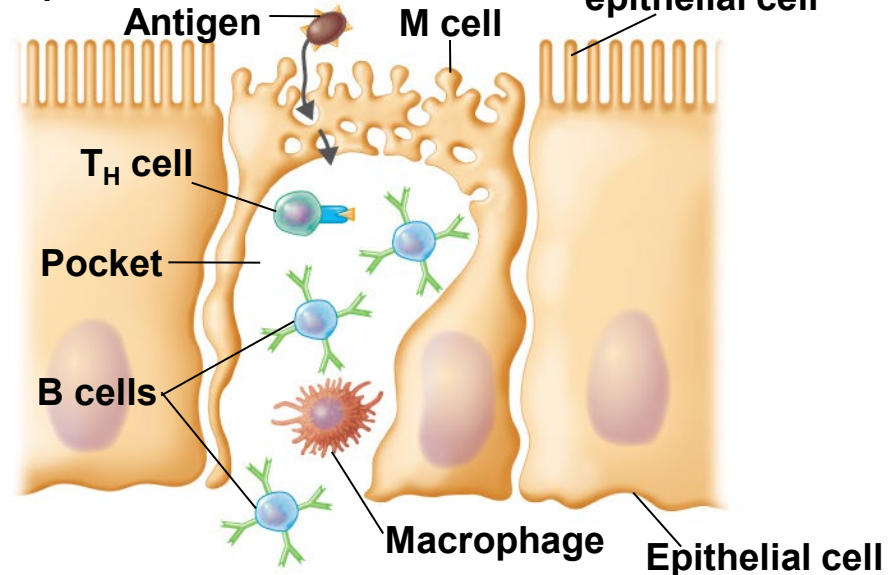
Tonsils have a similar function in bucal cavity!



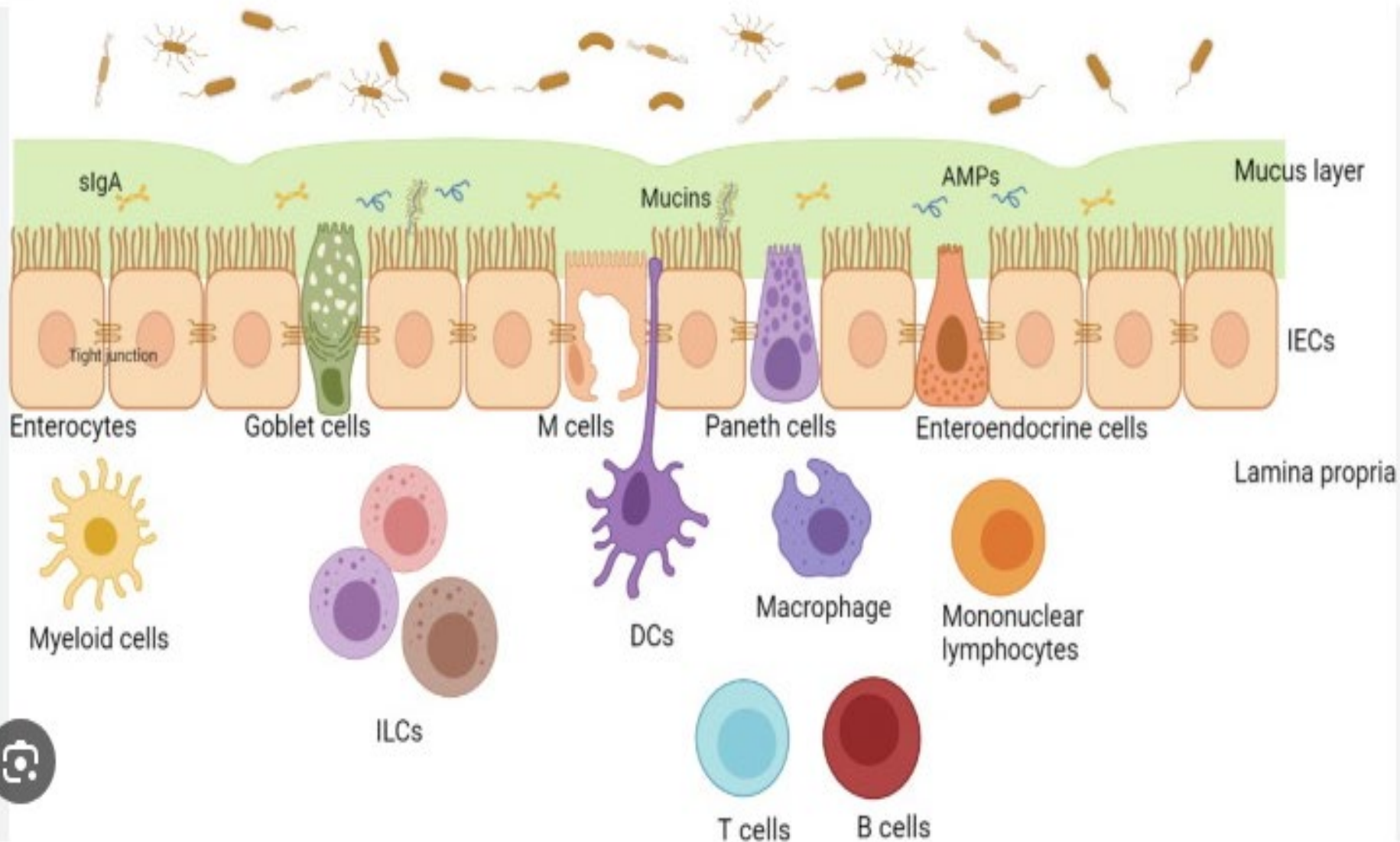
(a) M cell on Peyer's patch.

Note the tips of the closely packed microvilli on the surrounding epithelial cells.

SEM 1  $\mu\text{m}$



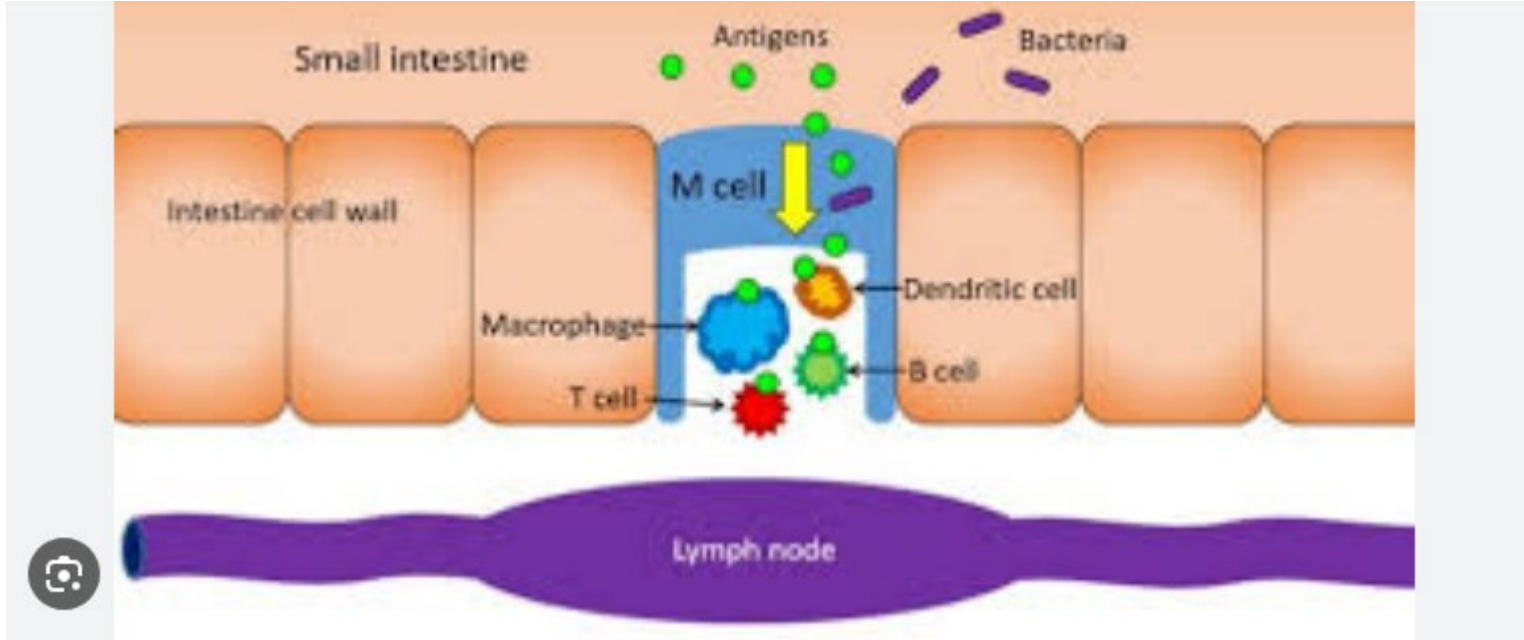
(b) M cells facilitate contact between the antigens passing through the intestinal tract and cells of the body's immune system.



Intestinal Lumen - an overview | ScienceDirect Topics

Visit >

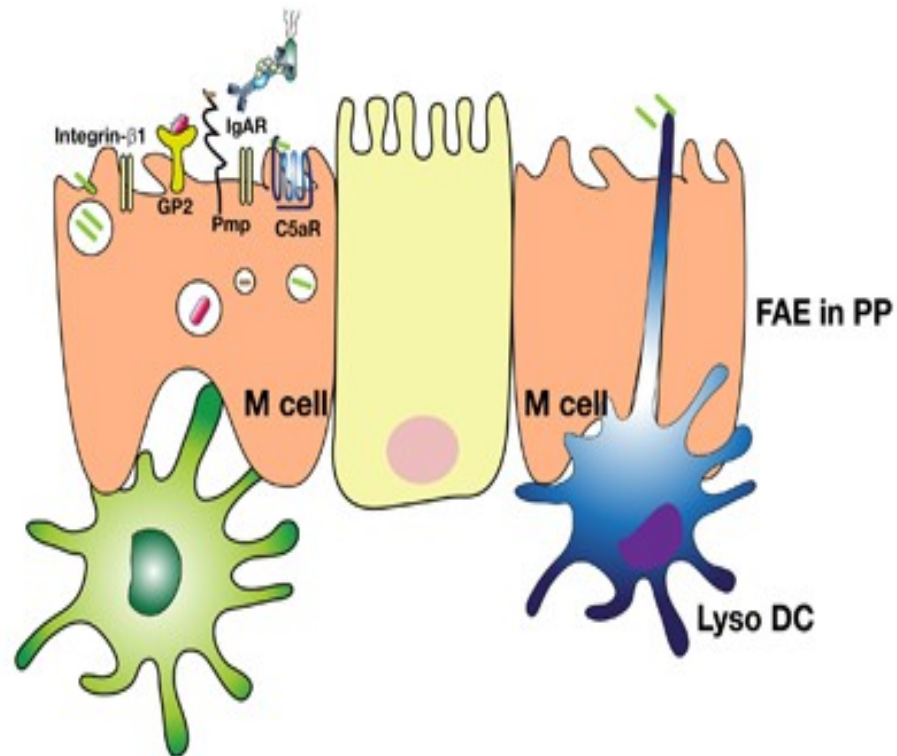
Note: tight junctions between epithelial cells. Function?



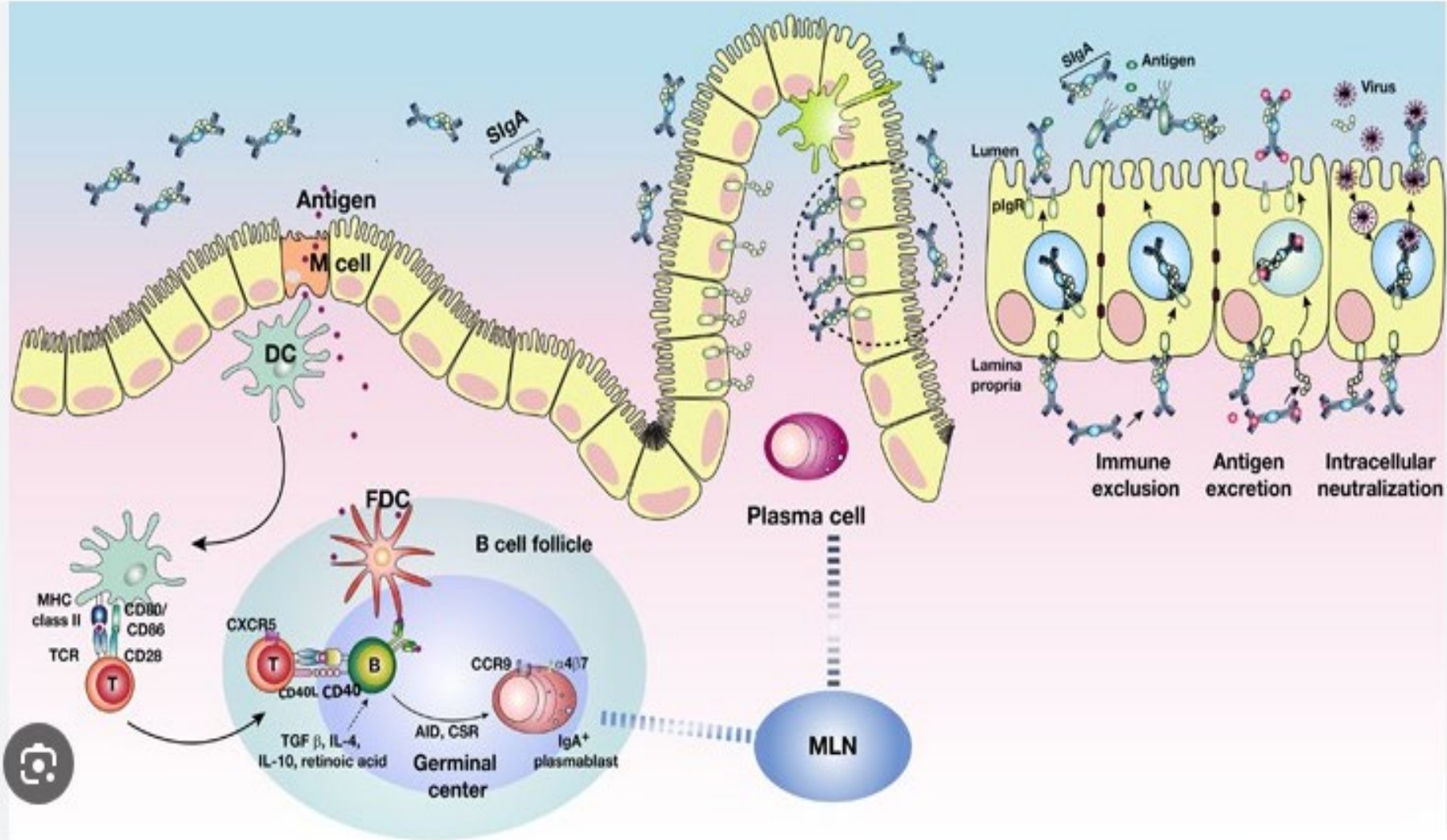
① M cell-mediated non-specific transcytosis

② M cell-specific receptor-mediated transcytosis

③ Antigen sampling through M-cell transcellular pore

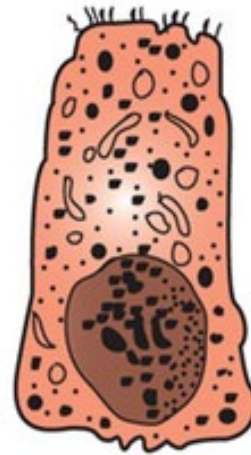

Antigen targeting to M cells for enhancing the efficacy of mucosal vaccines |  
Experimental & Molecular Medicine



Antigen targeting to M cells for enhancing the efficacy of mucosal vaccines |  
 Experimental & Molecular Medicine

# Intestine Epithelial Stem Cell



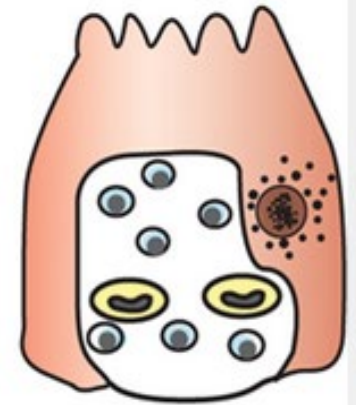
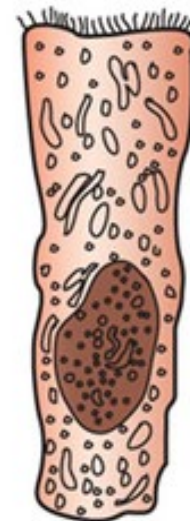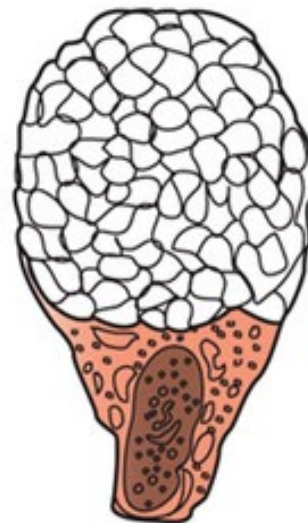
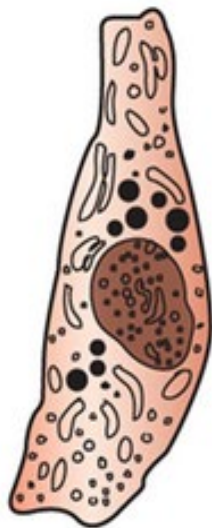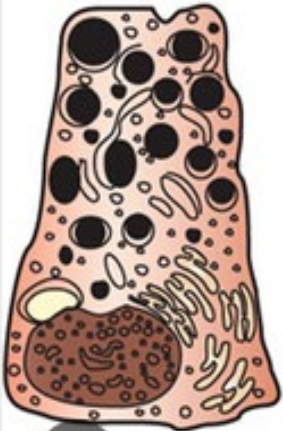Paneth cell

Neuroendocrine cell

Goblet cell

Enterocyte

M cell



# Chemical Messenger of the Small Intestines

---

Gastric glands, pyloric glands, and epithelial cells of the duodenum have various kinds of **enteroendocrine cells** that produce as many as 20 chemical messengers

some are **hormones** enter blood and stimulate distant cells

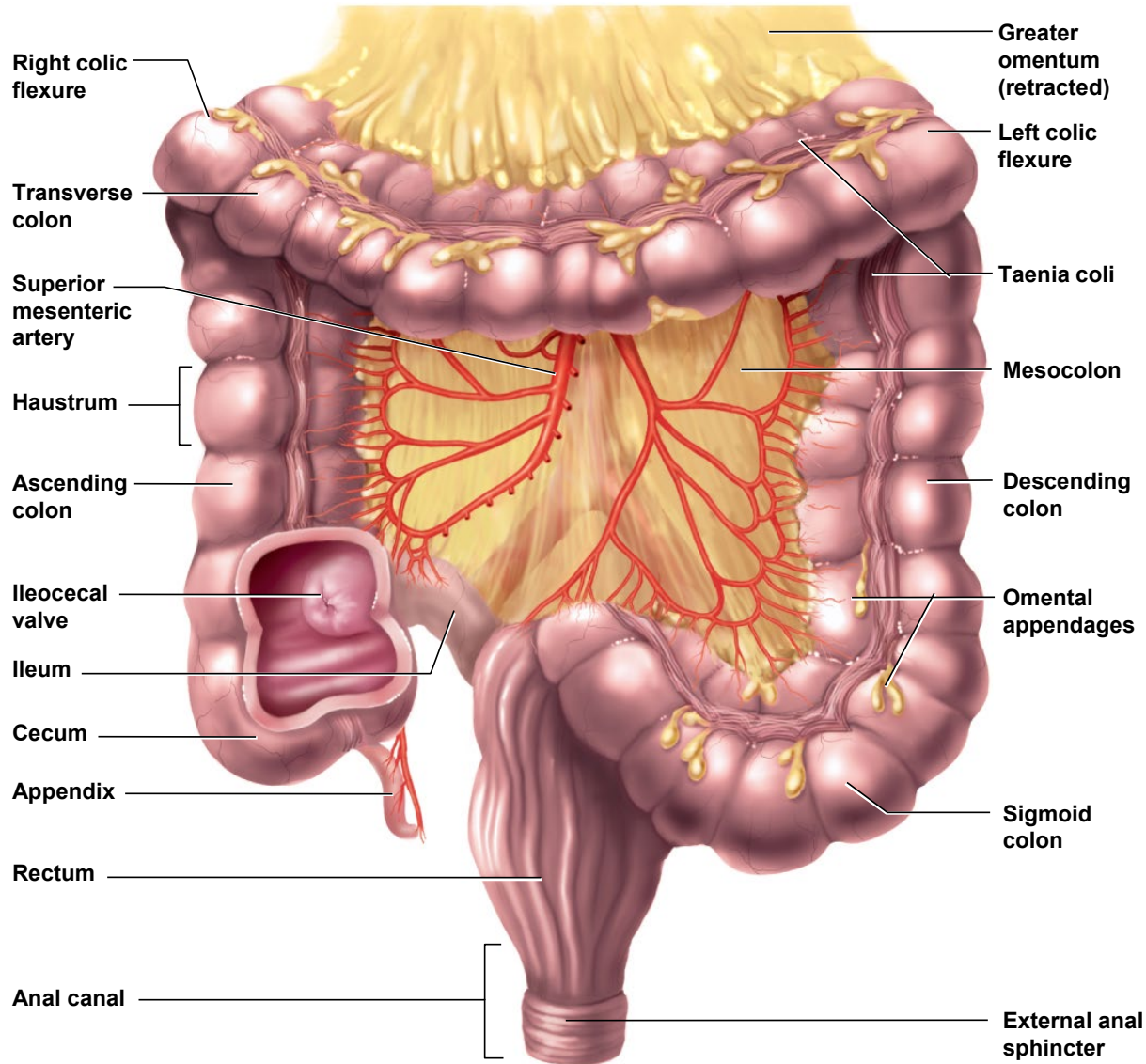
others are **paracrine** secretions that stimulate neighboring cells

Some of these chemical messengers are peptides and are produced in both the digestive tract and the central nervous system /// these are called **gut-brain peptides**

Substance P, vasoactive intestinal peptide (VIP), gastric inhibitory peptide (GIP), neuropeptide Y (NPY)

**Secretin, cholecystokinin, gastric inhibiting peptide, and glucose dependent insulinotropic peptide** (secreted by duodenum / know the action of these enteroendocrine hormones)

# Anatomy of Large Intestine



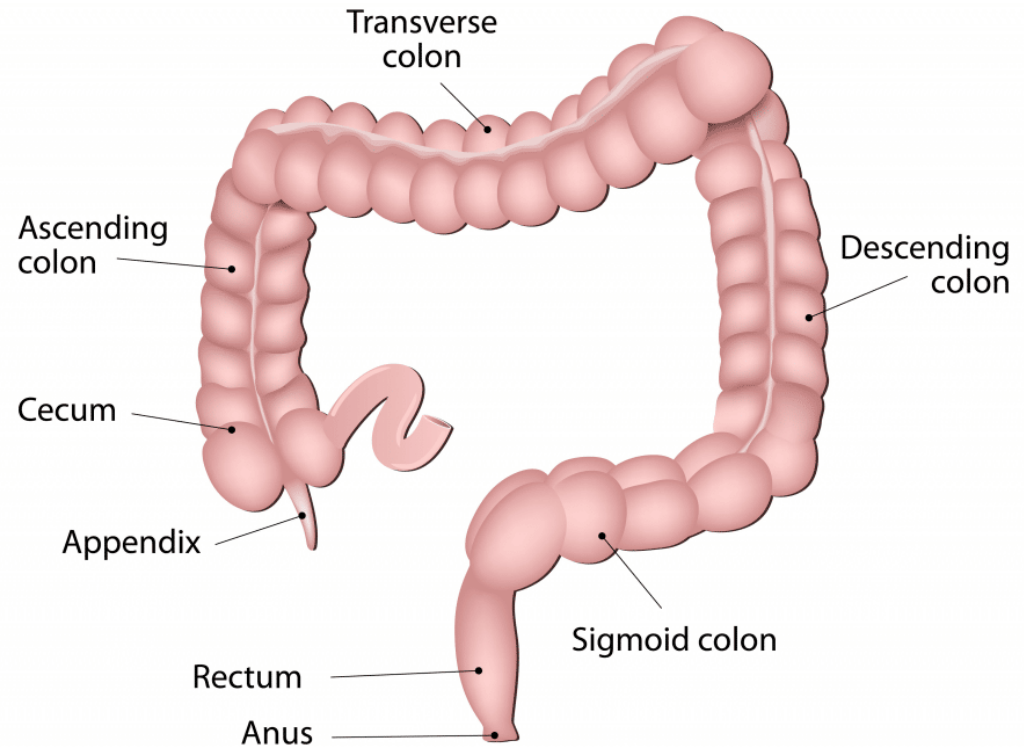
# Gross Anatomy of Large Intestine

---

Large intestine receives about **500 mL of indigestible residue per day**

Reduces it to about 150 mL of feces by absorbing water and salts

Feces eliminated by the **defecation reflex**



# Large Intestine's Microscopic Anatomy

---

## Mucosa of large intestine

Simple columnar epithelium through entire large intestine

**Anal canal** has nonkeratinized stratified squamous epithelium in its lower half // provides abrasion resistance

No circular folds or villi to increase surface area

Intestinal crypts - glands sunken into lamina propria

Greater density of mucous-secreting goblet cells

Lamina propria and submucosal layers have large amount of lymphatic tissue /// provide protection from the bacteria that densely populate the LI

# Distal End of the Large Intestine

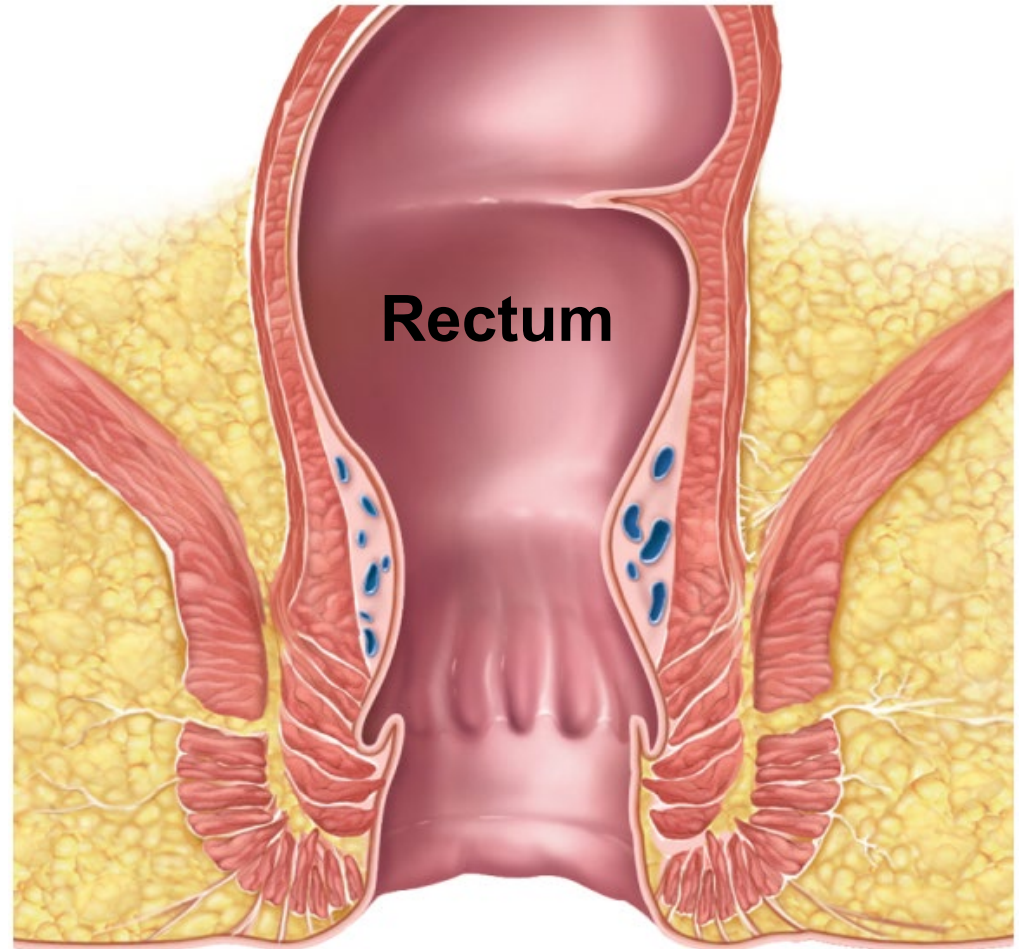
---

## Rectum

Stores fecal material prior to defecation

Portion ending at anal canal

Has 3 curves and 3 infoldings the transverse rectal folds (rectal valves)



# Gross Anatomy of Large Intestine

---

Muscularis externa unusual structure

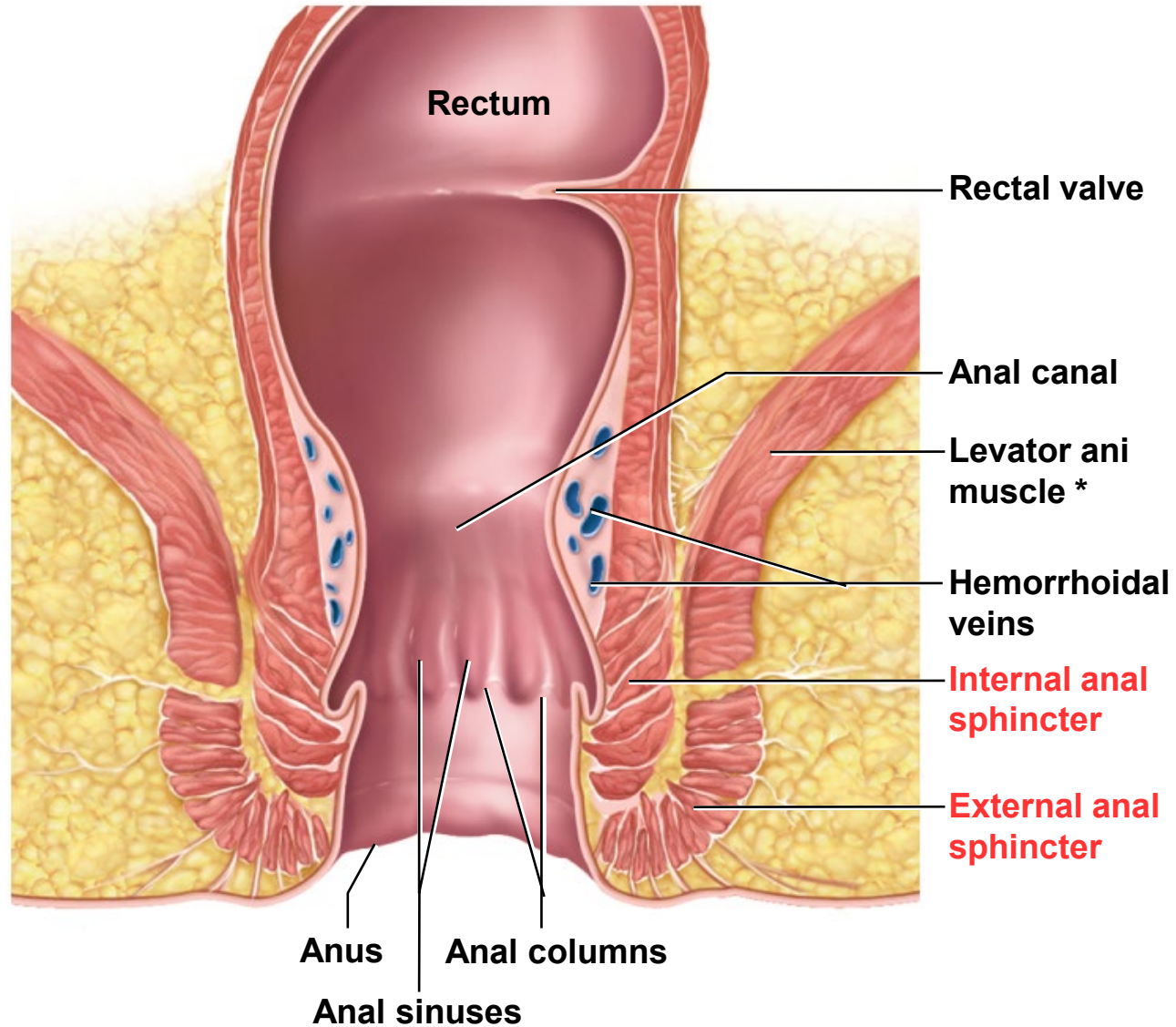
taenia coli – longitudinal fibers concentrated in three thicken, ribbon like strips

haustra – pouches in the colon caused by the muscle tone of the taenia coli

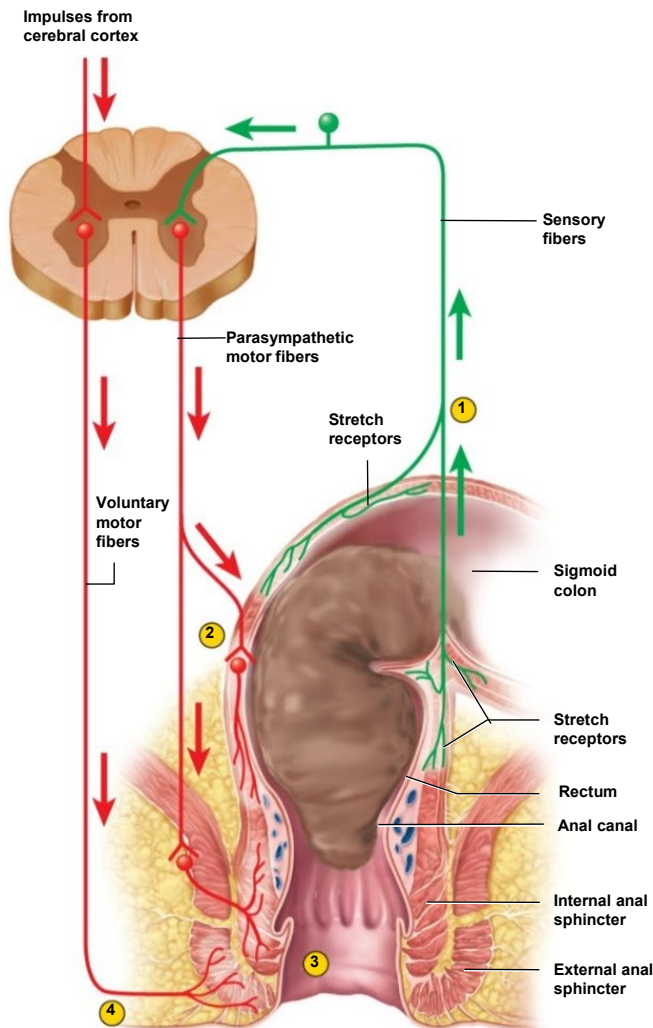
omental (epiploic) appendages – club-like, fatty pouches of peritoneum adhering to the colon – unknown function

- > **internal anal sphincter** - smooth muscle of muscularis externa
- > **external anal sphincter** - skeletal muscle of pelvic diaphragm

# Anatomy of Anal Canal



*Go to a dog park and watch dogs defecate to see the levator ani muscle's function!*



# Neural Control of Defecation

1. filling of the rectum
2. reflex contraction of rectum and relaxation of internal anal sphincter
3. voluntary relaxation of external sphincter

- 1 Feces stretch the rectum and stimulate stretch receptors, which transmit signals to the spinal cord.
- 2 A spinal reflex stimulates contraction of the rectum.
- 3 The spinal reflex also relaxes the internal anal sphincter.
- 4 Impulses from the brain prevent untimely defecation by keeping the external anal sphincter contracted. Defecation occurs only if this sphincter also relaxes.

# Large Intestine Absorption and Motility

---

Large intestine takes about **12 to 24 hours to reduce the residue of a meal to feces** /// does not chemically change the residue /// reabsorbs water and electrolytes

**Feces** consist of 75% water and 25% solids - 30% bacteria, 30% undigested fiber, 10 – 20% fat, small amount of mucus and sloughed epithelial cells

**Haustral contractions** occur every 30 minutes /// this kind of colonic motility is a form of segmentation /// distension of a haustrum stimulates it to contract

**Mass movements** occur 1 to 3 times a day /// triggered by **gastrocolic** and **duodenocolic reflexes** /// filling of the stomach and duodenum stimulates motility of the colon /// moves residue for several centimeters with each contraction

# Bacterial Flora and Intestinal Gas

---

**Bacterial flora** populate large intestine // about **800 species** of bacteria

ferment cellulose and other undigested carbohydrates // we absorb resulting sugars

help in **synthesis vitamins B and K**

## **Flatus** - intestinal gas

7 to 10 L of gas produced daily // Most reabsorbed

average person expels **500 mL per day** (flatus) // most of this gas is swallowed air and odorless

bacteria produce hydrogen sulfide, methane, **indole** and **skatole** /// produce odor of flatus and feces // hydrogen gas may explode during electrical cauterization used in surgery

# Accessory Organs of Digestive System

---

Teeth

Tongue

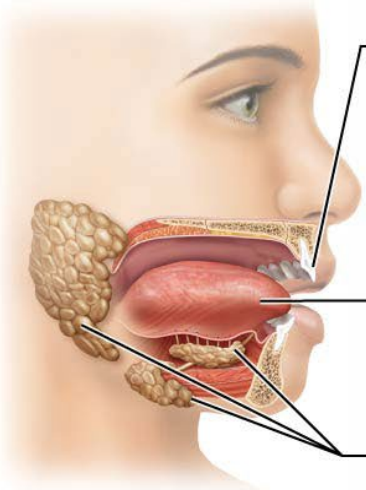


Salivary Glands

Liver

Pancreas

Gall Bladder

## Summary of the structure and function of the accessory digestive organs.

ORGAN	STRUCTURAL PROPERTIES	FUNCTIONAL ROLES
 <p><b>Teeth</b></p>	<ul style="list-style-type: none"> <li>• Two sets: primary and secondary dentition</li> <li>• Consist of a crown above the gum and a root embedded in bone</li> <li>• Composed of inner pulp cavity surrounded by dentin, which in turn is surrounded by enamel or cementum</li> </ul>	<ul style="list-style-type: none"> <li>• Mechanical digestion (mastication)</li> </ul>
<p><b>Tongue</b></p>	<ul style="list-style-type: none"> <li>• Consists of skeletal muscle with overlaying stratified squamous epithelium</li> <li>• Surface contains papillae</li> </ul>	<ul style="list-style-type: none"> <li>• Mechanical digestion</li> <li>• Propulsion (swallowing)</li> <li>• Sense of taste</li> </ul>
<p><b>Salivary glands</b></p>	<ul style="list-style-type: none"> <li>• Three sets: parotid glands, submandibular glands, and sublingual glands</li> <li>• Consist of mucous cells and serous cells</li> </ul>	<ul style="list-style-type: none"> <li>• Secrete saliva, which assists in chemical digestion, deters the growth of harmful microorganisms, and moistens food to assist in swallowing and mechanical digestion</li> <li>• Chemical digestion of carbohydrates</li> </ul>
 <p><b>Pancreas</b></p>	<ul style="list-style-type: none"> <li>• Consists of pancreatic acini, composed of acinar cells surrounding a duct</li> </ul>	<ul style="list-style-type: none"> <li>• Secretes enzymes that catalyze chemical digestion of lipids, carbohydrates, proteins, and nucleic acids</li> <li>• Secretes bicarbonate ions to neutralize acidic chyme</li> </ul>
 <p><b>Liver</b></p>	<ul style="list-style-type: none"> <li>• Consists of hexagonal liver lobules surrounding a central vein</li> <li>• Liver lobules contain plates of hepatocytes</li> </ul>	<ul style="list-style-type: none"> <li>• Mechanical digestion (via bile production)</li> <li>• Excretion (excretes wastes in bile)</li> </ul>
<p><b>Gallbladder</b></p>	<ul style="list-style-type: none"> <li>• Muscular sac on the posteroinferior liver</li> </ul>	<ul style="list-style-type: none"> <li>• Mechanical digestion (stores, concentrates, and releases bile)</li> </ul>

# The Liver

---

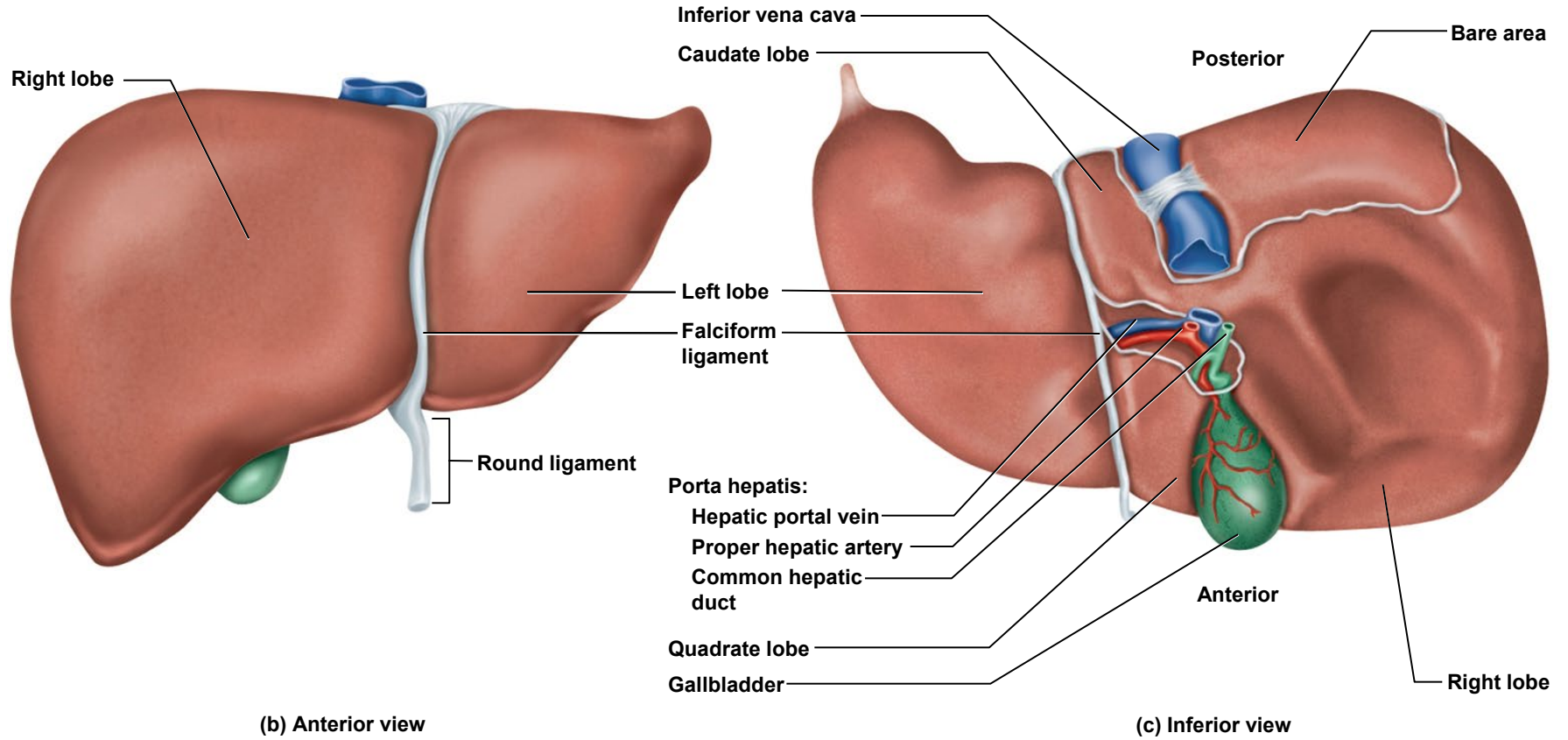
Reddish brown gland located immediately inferior to the diaphragm

body's **largest gland** // weighs about 1.4 kg (3 pounds)

variety of critical functions

**secretes bile** which contributes to digestion ///  
two major components = **bile pigments and bile acids**

# Gross Anatomy of Liver



# Functions of Hepatocytes

---

After a meal, the hepatocytes **absorb nutrients from the blood** /// glucose, amino acids, iron, vitamins, and other nutrients for metabolism or storage (eg glycogen)

**Removes and degrades** /// hormones, toxins, bile pigments, and drugs /// many macrophage in liver

**Secretes into the blood** /// albumin, lipoproteins, clotting factors, activates angiotensin, complement proteins, and other products

In between meals, hepatocytes breaks down stored glycogen and **releases glucose** into the blood

**Produces bile** / bile transported to and stored in gall bladder

Hepatocytes also able to preform **gluconeogenesis and lipogenesis**

# Microscopic Anatomy of Liver

---

**Bile canaliculi** – narrow channels into which the liver secretes bile

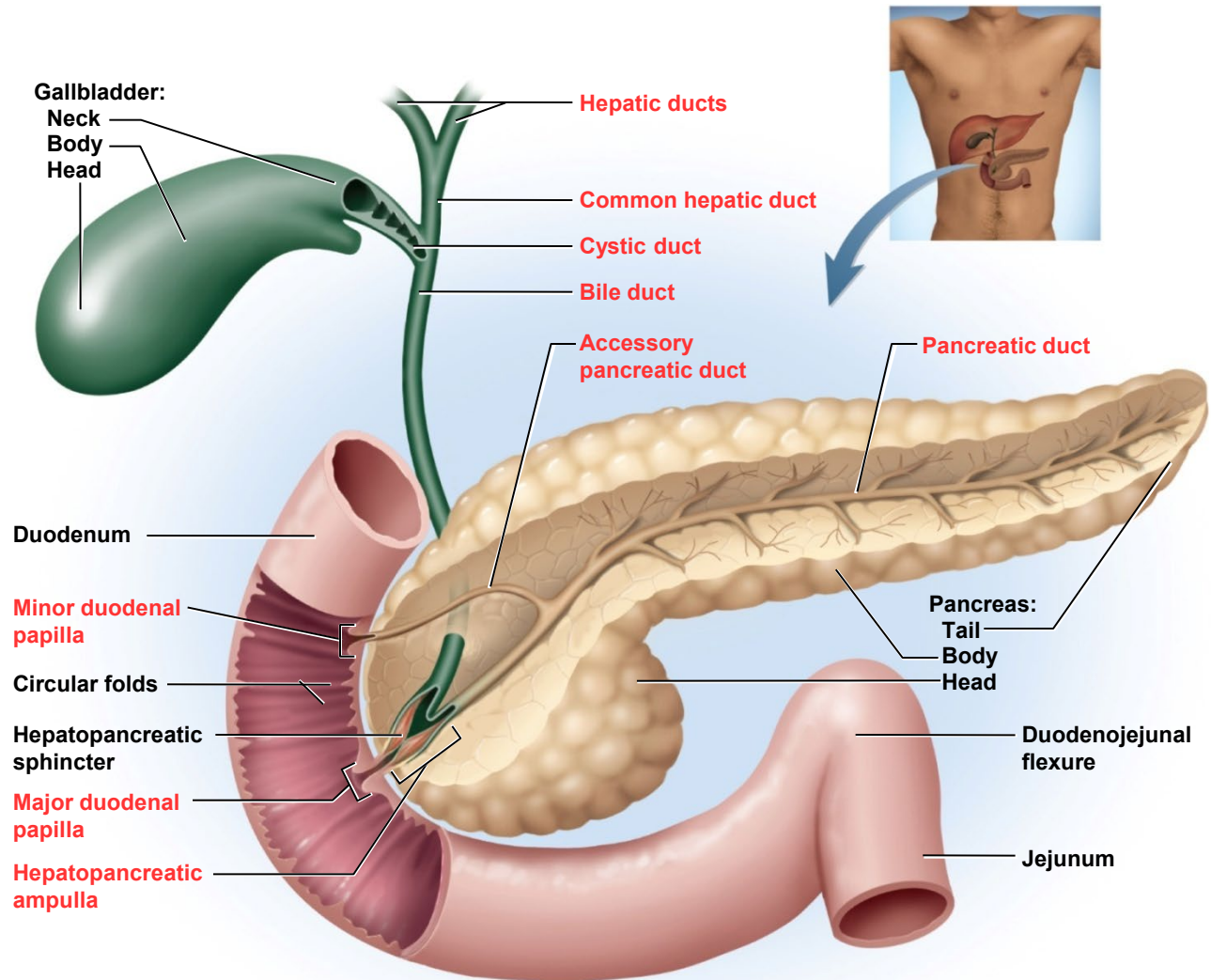
bile passes into bile **ductules** of the triads

ultimately into the **right and left hepatic ducts**

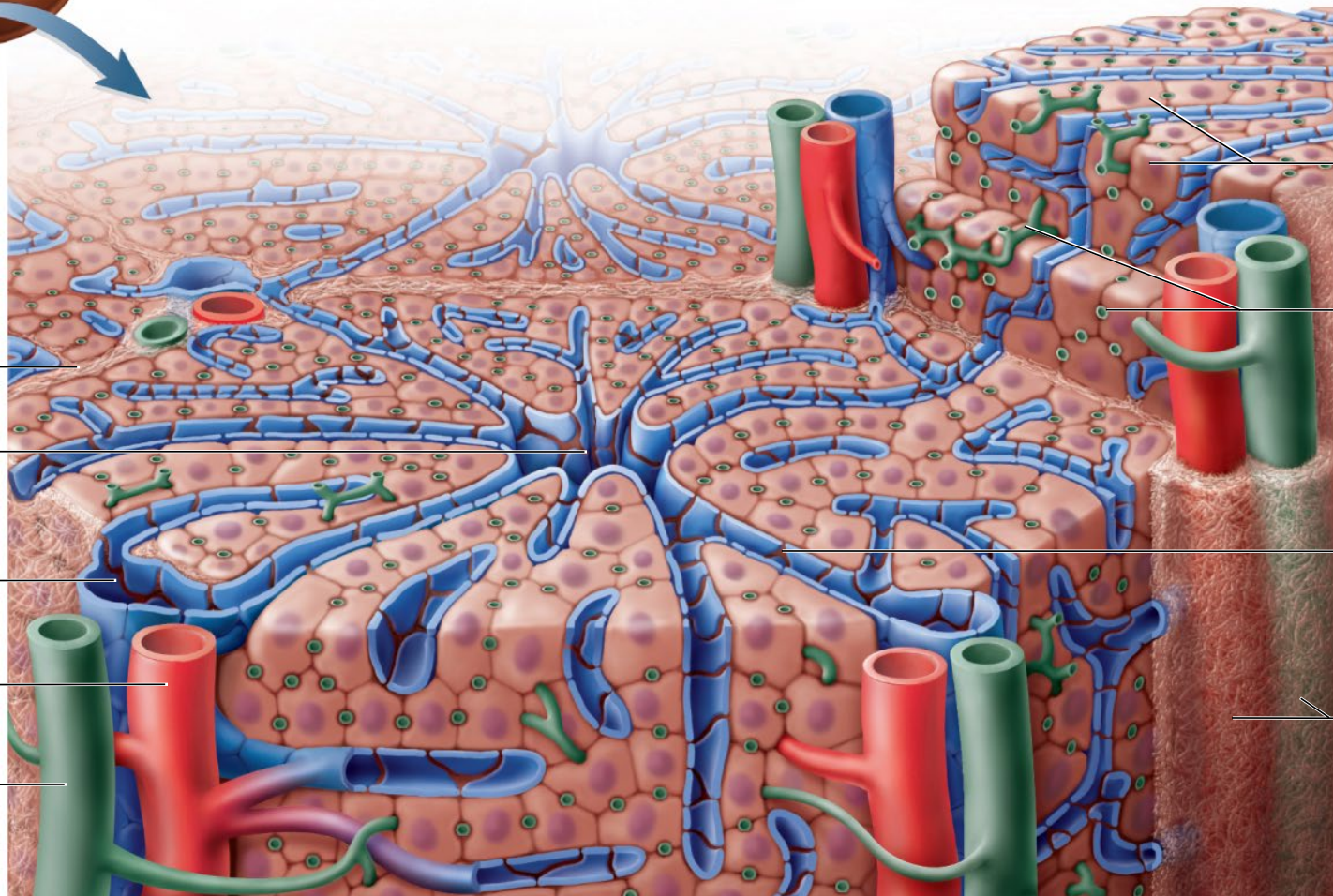
**common hepatic duct** – formed from convergence of right and left hepatic ducts on inferior side of the liver

**cystic duct** coming from gall bladder joins common hepatic duct

# Gross Anatomy of the Gallbladder, Pancreas, and Bile Passages



# Microscopic Anatomy of Liver



Stroma

Central vein

Hepatic triad:

Branch of hepatic portal vein

Branch of proper hepatic artery

Bile ductule

Hepatocytes

Bile canaliculi

Hepatic sinusoid

Stroma

(a)

# Bile

---

Bile – yellow-green fluid containing minerals, cholesterol, neutral fats, phospholipids

Primary secretions are **bile acids (also called salts) and bile pigments**

**Liver secretes about 500 – 1000 ml of bile daily**

Bile gets to the gallbladder by first filling the bile duct but if hepatopancreatic papillae closed fluid fills gallbladder

# Bile

---

**Bile pigments** /// **bilirubin** – principal pigment derived from the **decomposition of hemoglobin** /// bacteria in large intestine metabolize **bilirubin to urobilinogen** /// responsible for the **brown color of feces**

**Bile acids (also called bile salts)** /// steroids synthesized from cholesterol /// **gallstones** may form if bile becomes excessively concentrated

**80% of bile acids are reabsorbed** in the ileum and returned to the liver /// hepatocytes absorb and resecret them /// **enterohepatic circulation** – this route secretion, reabsorption, and resecretion of bile acids two or more times during digestion of an average meal

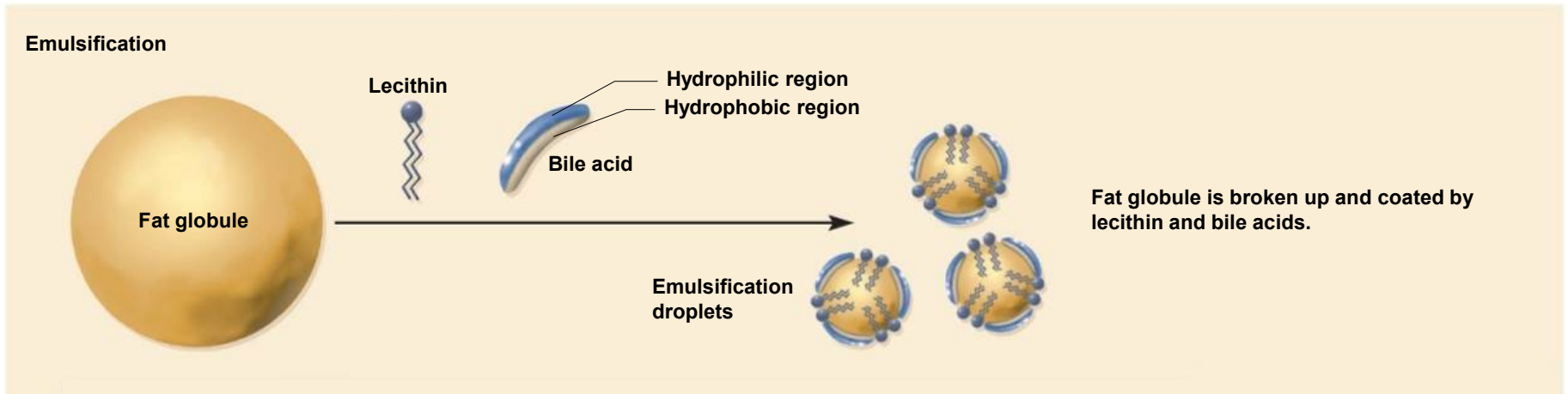
**20% of the bile acids are excreted in the feces** /// this is the body's only way of eliminating excess cholesterol /// liver synthesizes new bile acids from cholesterol to replace those lost in feces

Another molecule associated with the bile acids is **lecithin**, a phospholipid that helps in fat digestion and absorption

# Emulsification

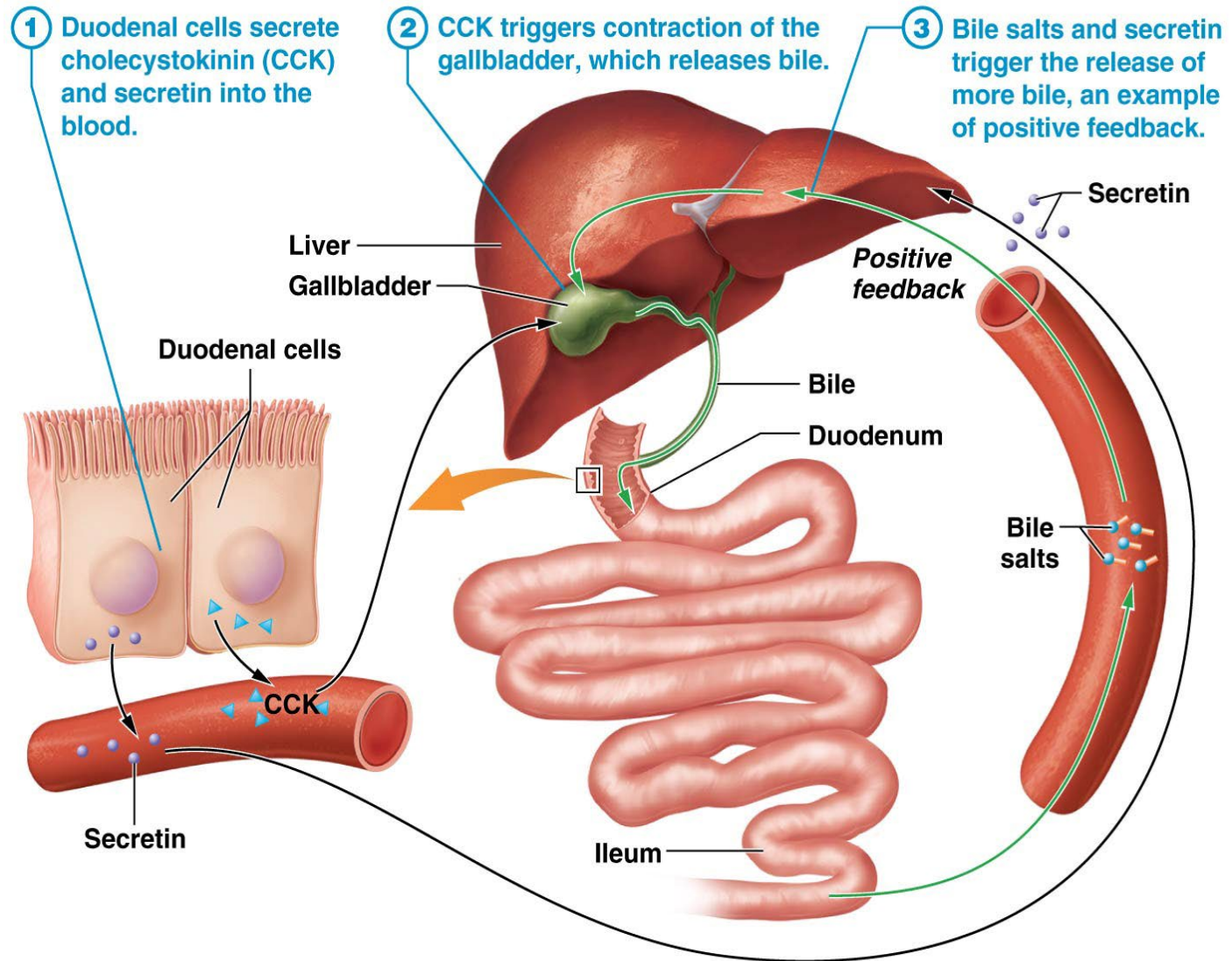
## Action of Bile Acids and Lecithin

Copyright © The McGraw-Hill Companies, Inc. Permission required for reproduction or display.



More on this topic covered in metabolism lecture.

# Secretion of Bile



Note: Secretin also stimulate cells lining pancreatic ducts and bile duct to secrete bicarbonate. Why?

# The Pancreas

Spongy **retroperitoneal gland** posterior to the greater curvature of the stomach

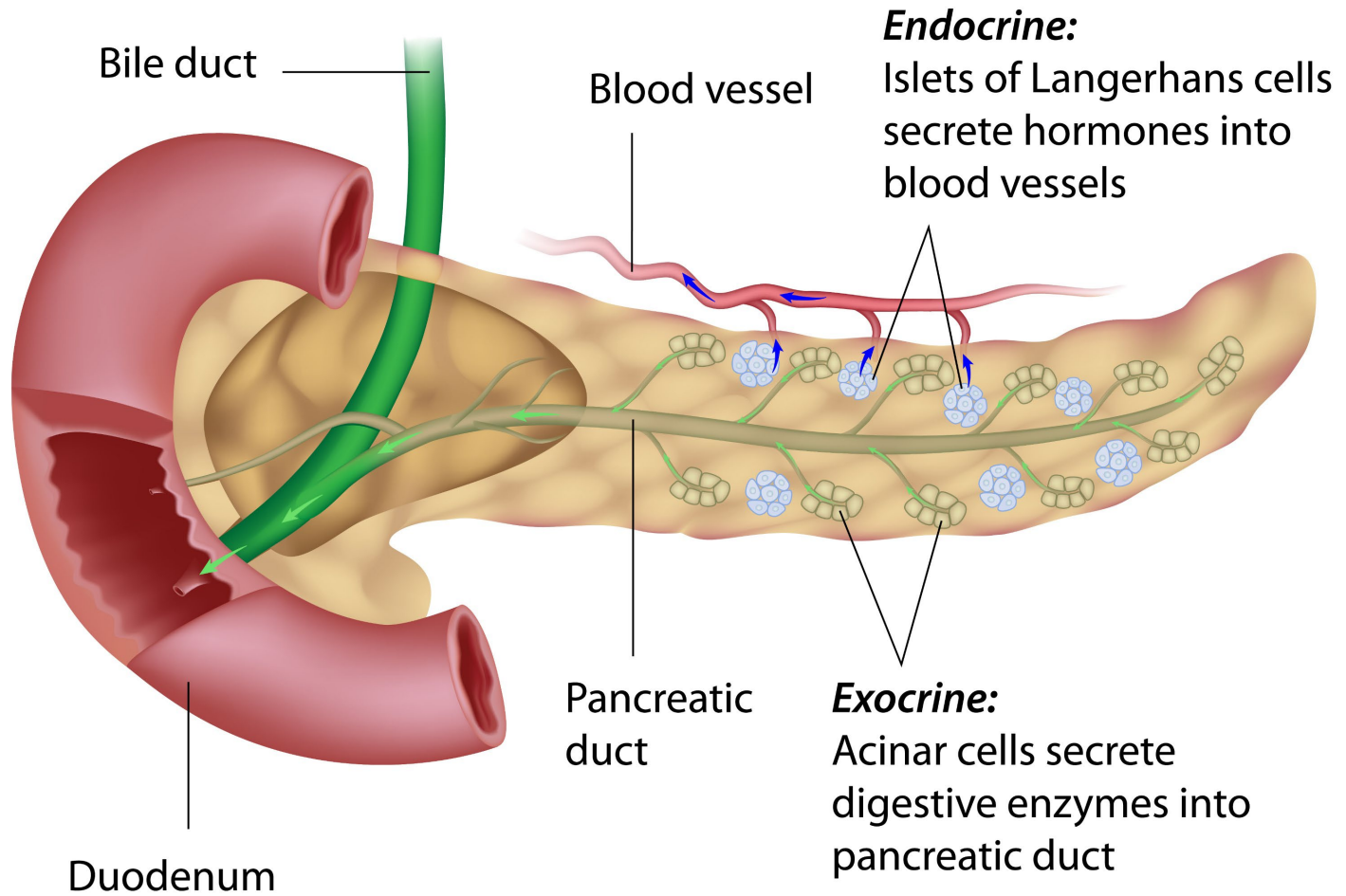
measure 12 to 15 cm long, and 2.5 cm thick

has head encircled by duodenum, body, midportion, and a tail on the left

both an endocrine and exocrine gland

**endocrine portion** – pancreatic islets that secrete **insulin** and **glucagon**

**exocrine portion** – 99% of pancreas that secretes 1200 to 1500 mL of pancreatic juice per day /// \_secretory acini release their secretion into small ducts that converge on the main **pancreatic duct**



# The Pancreas

---

**Pancreatic duct** runs lengthwise through the middle of the gland

joins the bile duct at the **hepatopancreatic ampulla**

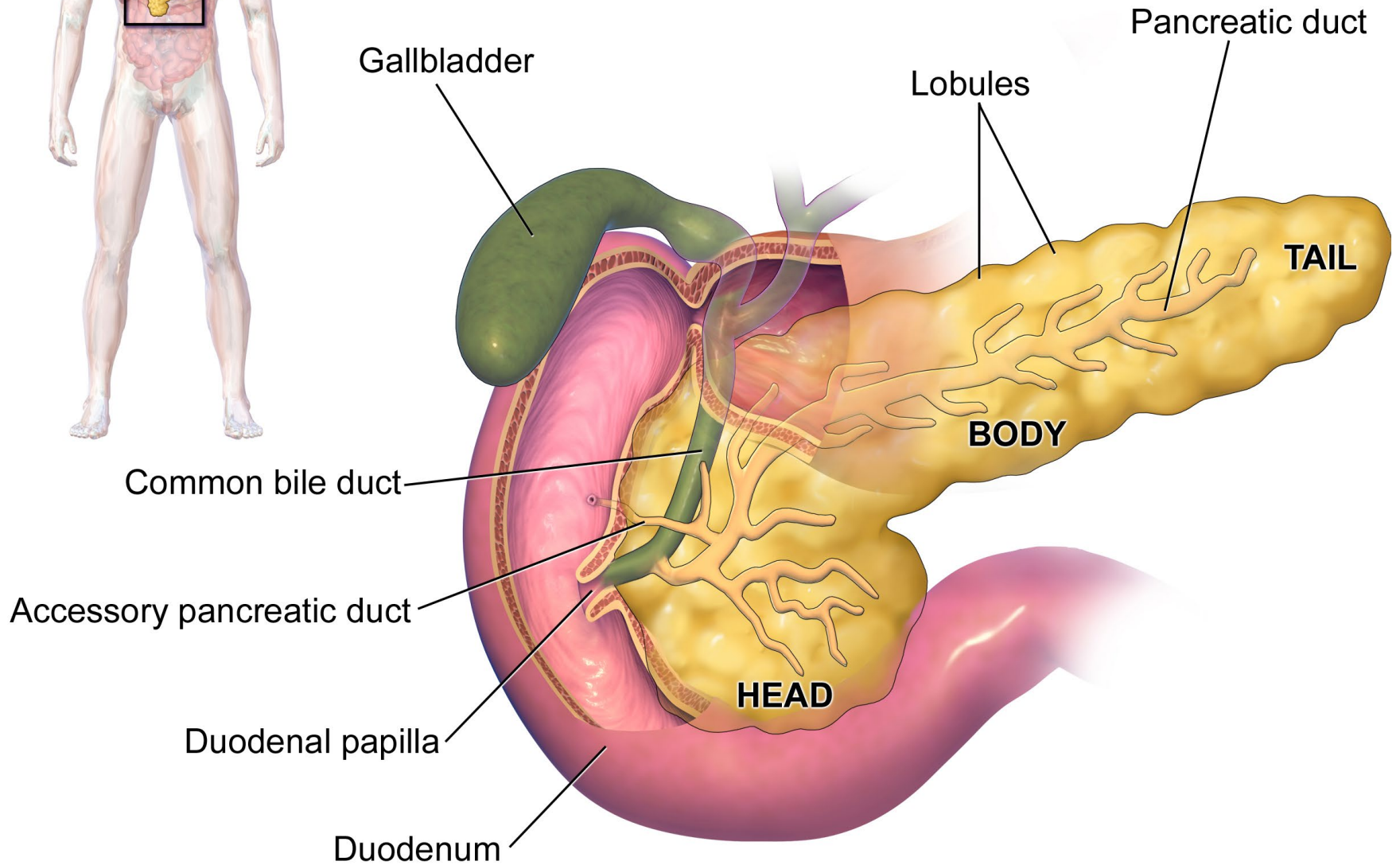
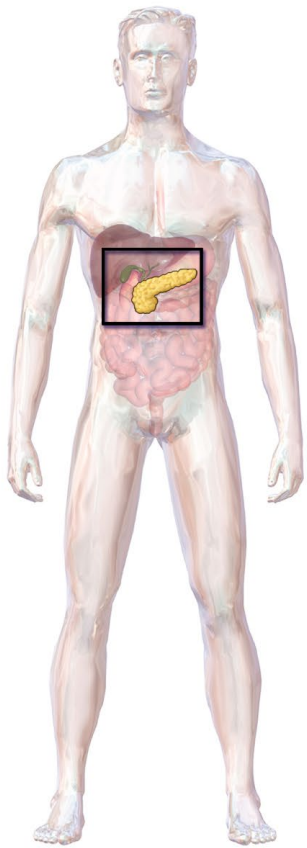
**hepatopancreatic sphincter** controls release of both bile and pancreatic juice into the duodenum

## **Accessory pancreatic duct**

smaller duct that branches from the main pancreatic duct

opens independently into the duodenum

**bypasses the sphincter** and allows pancreatic juice to be released into the duodenum even when bile is not



# The Pancreas

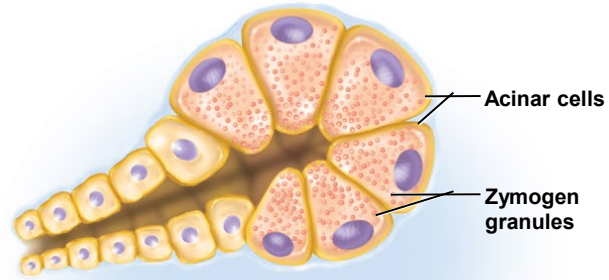
---

**Pancreatic juice** – alkaline mixture of water, enzymes, zymogens, sodium bicarbonate, and other electrolytes

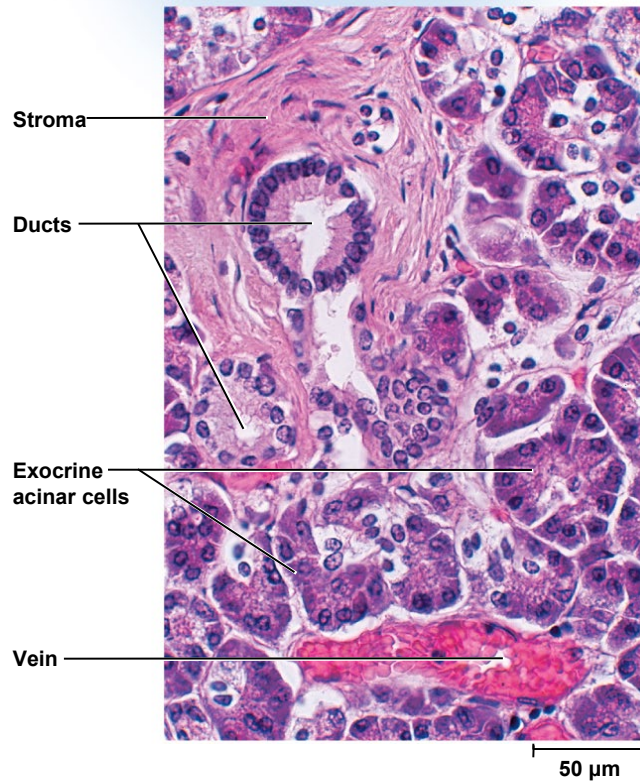acini secrete the enzymes and zymogens

**ducts** secrete bicarbonate /// required in order to **buffer HCl** from the stomach

# Pancreatic Acinar Cells



(a)



# Pancreatic Proteolytic Zymogens

---

## Trypsinogen

secreted by pancreas into intestinal lumen

converted to trypsin by enterokinase // enterokinase is a brush boarder enzyme of small intestine's mucosa

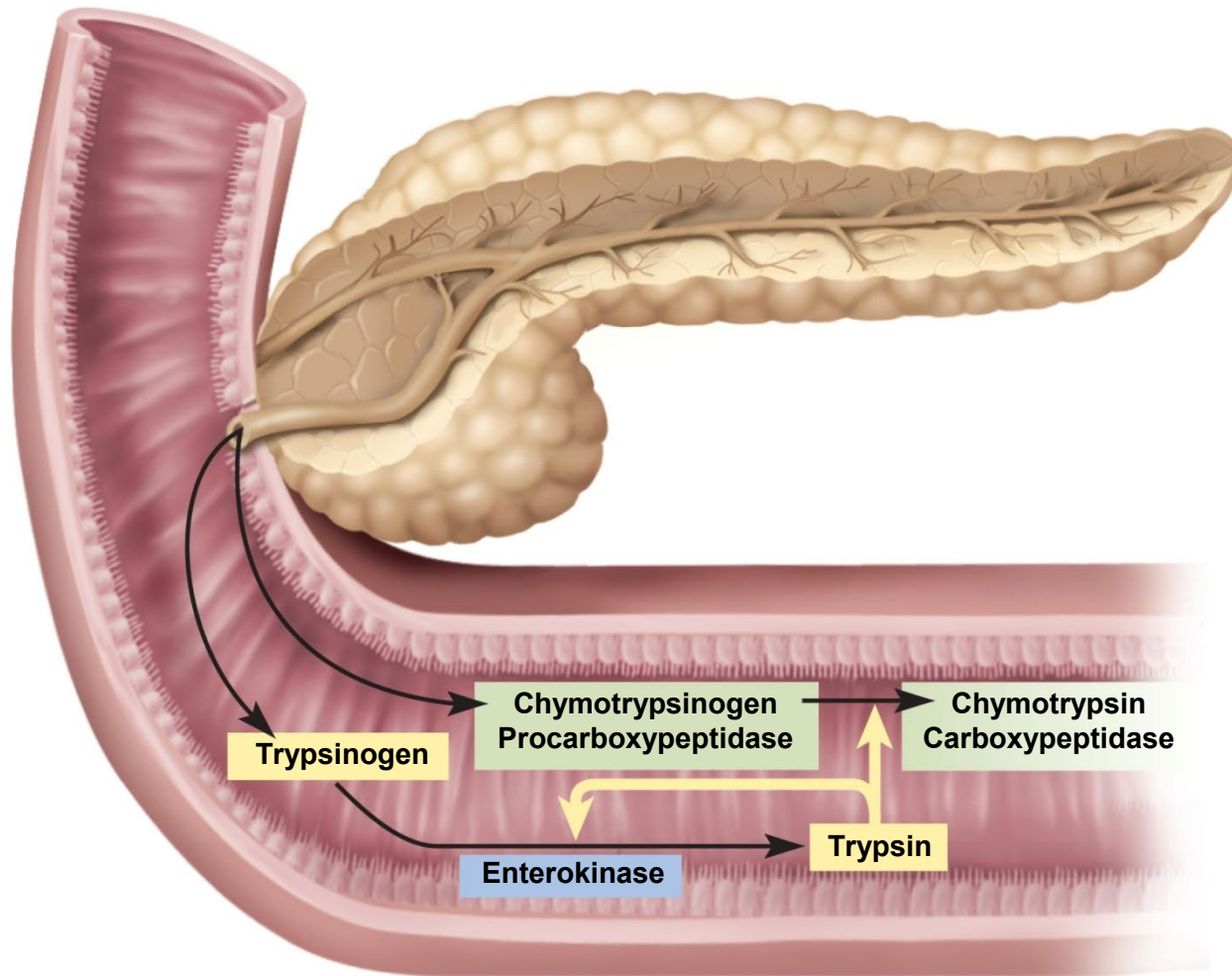
trypsin is autocatalytic – this means it converts trypsinogen into still more trypsin

trypsin = proteinolytic enzyme

Chymotrypsinogen /// this is converted to trypsinogen by trypsin

Procarboxypeptidase /// this is converted to carboxypeptidase by trypsin

# Activation of Pancreatic Enzymes in the Small Intestine



# Other Pancreatic Enzymes

---

**Pancreatic amylase** – digests starch

**Pancreatic lipase** – digests fat

**Ribonuclease** and **deoxyribonuclease** – digest RNA and DNA respectively

# Regulation of Pancreatic & Gall Bladder Secretion (1 of 2)

---

**Three stimuli** are chiefly responsible for the release of pancreatic and bile secretions

- 1.) acetylcholine
- 2. cholecystokinin
- 3. secretin

**Acetylcholine (ACh)** - from vagus nerves and enteric nerves // stimulates acini to secrete their enzymes during the **cephalic phase** of gastric control even **before food is swallowed**

enzymes remain in acini and ducts until chyme enters the duodenum

# How Pancreatic & Gall Bladder Secretion Regulated (2 of 2)

---

**Cholecystikin (CCK)** - secreted by mucosa of duodenum in response to arrival of fats in small intestine

stimulate pancreatic acini cells to **secrete digestive enzymes**

strongly stimulates gall bladder to release bile

induces **relaxation of hepatopancreatic sphincter** that allows both bile and pancreatic digestive enzymes into the duodenum

**Secretin** - released from duodenum in response to acidic chyme arriving from the stomach // stimulates ducts in both liver and pancreas **to secrete more sodium bicarbonate** // raising pH to level pancreatic and intestinal digestive enzymes require

# Gallstones

---

**Gallstones (biliary calculi)** - hard masses develop in either the gallbladder or bile ducts

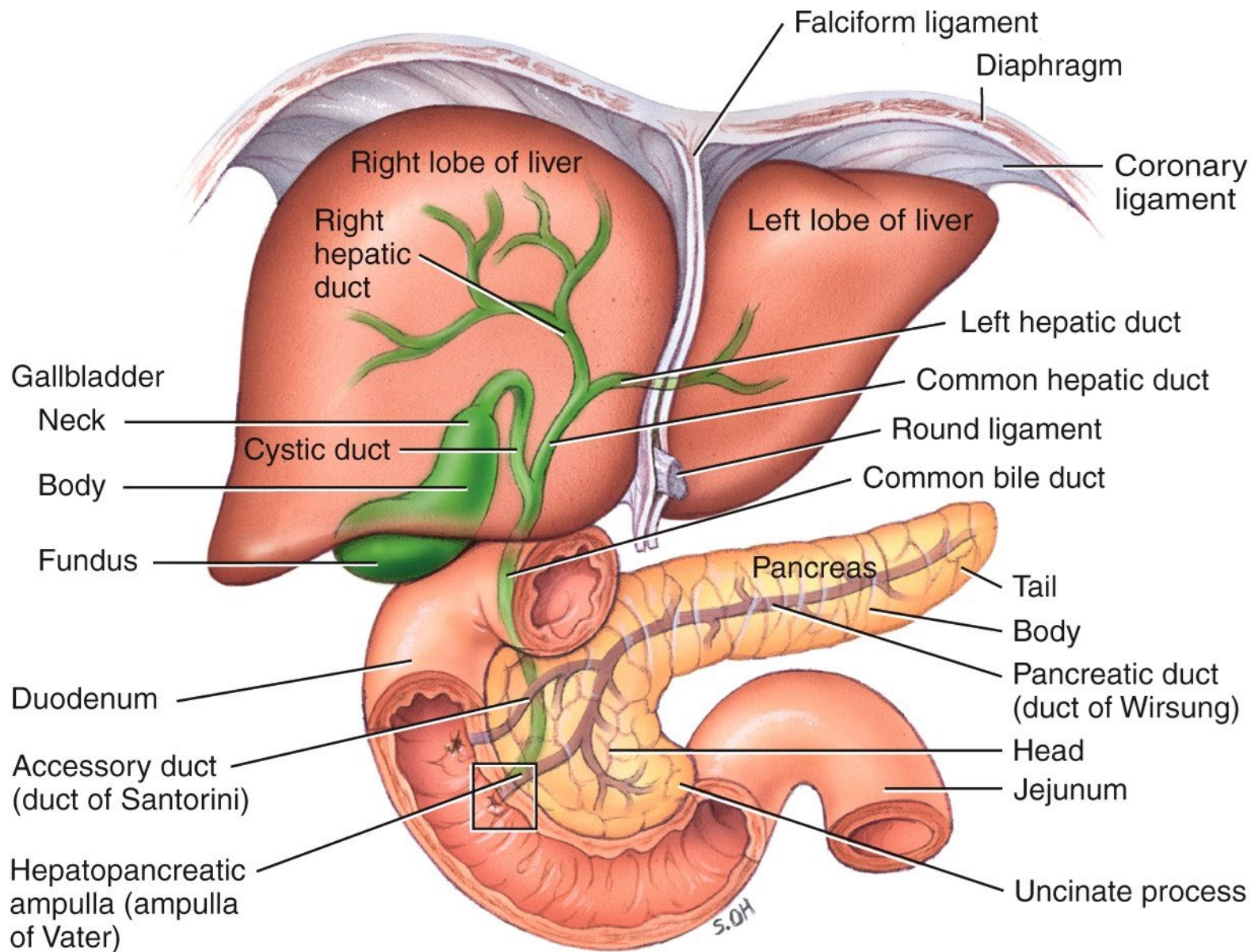
Composed of cholesterol, calcium carbonate, and bilirubin

Gallstones may cause obstruction within ducts // very painful // prevents essential molecules for proper fat metabolism from reaching the duodenum

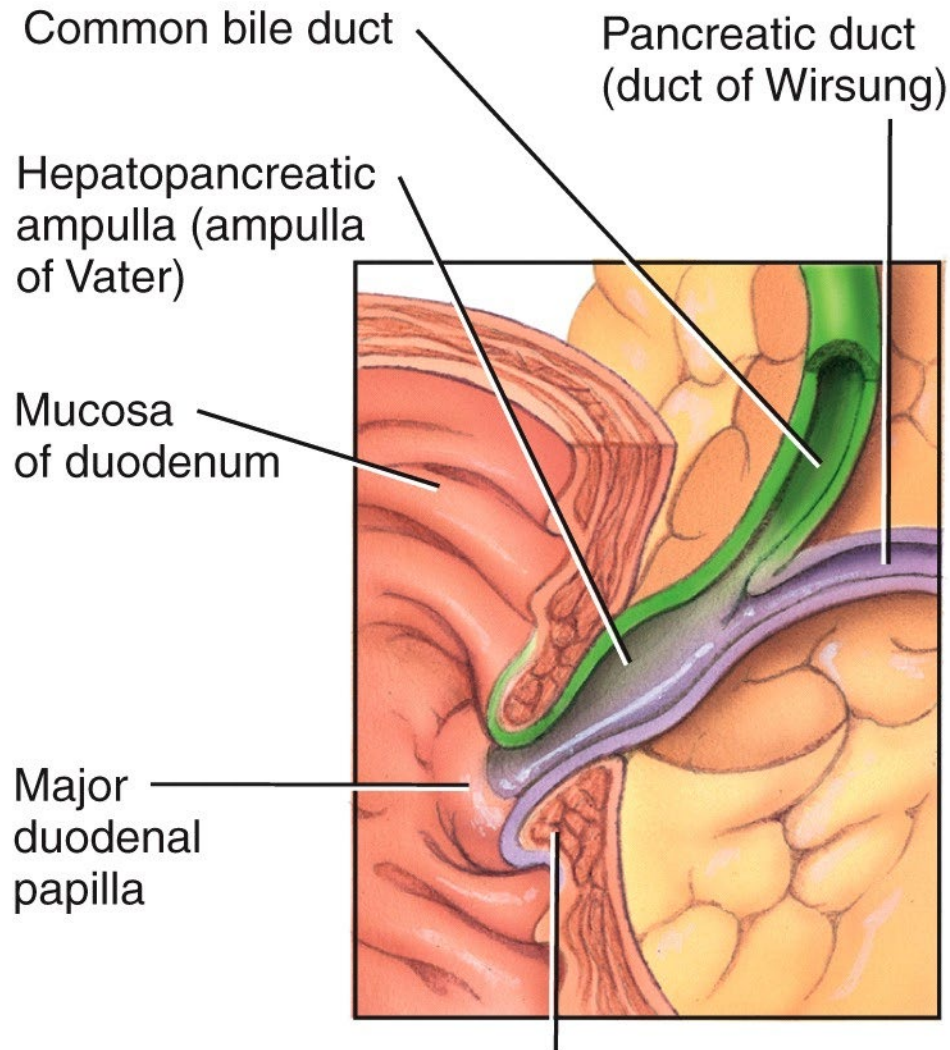
Obstruction may cause jaundice - yellowing of skin and sclera due to bile pigment accumulation, poor fat digestion, and impaired absorption of fat-soluble vitamins

**lithotripsy** - use of ultrasonic vibration to pulverize stones without surgery

**cholelithiasis** - formation of gallstones /// most common in obese women over 40 due to excess cholesterol

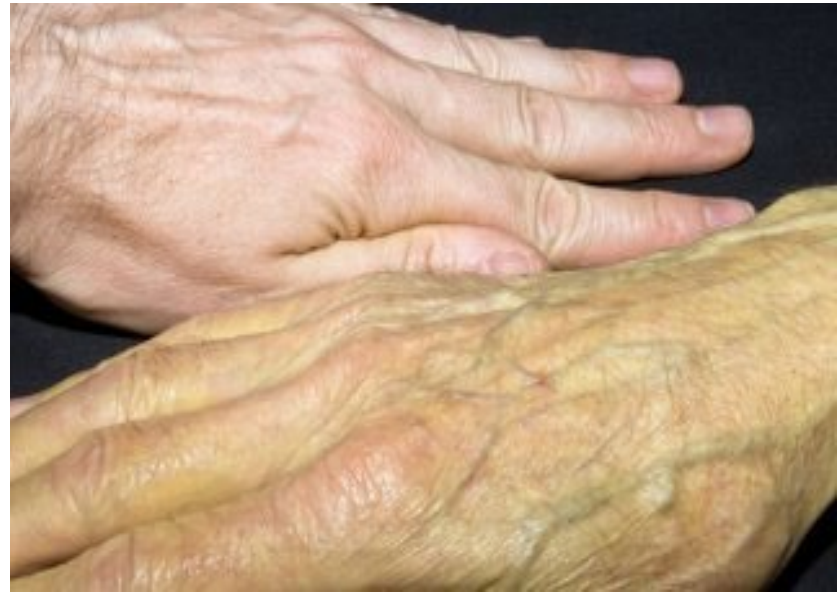
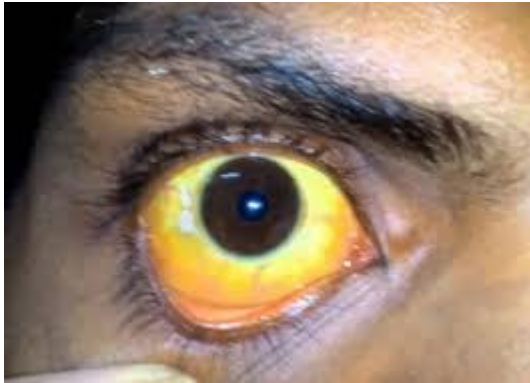
(a) Anterior view

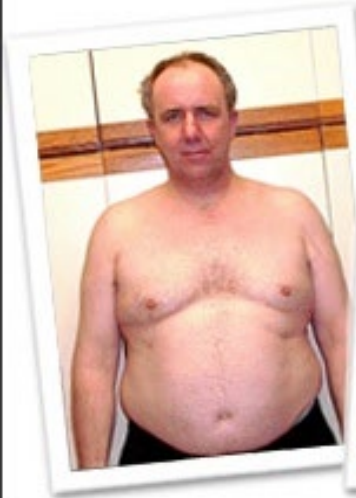

Sphincter of the hepatopancreatic ampulla (sphincter of Oddi)

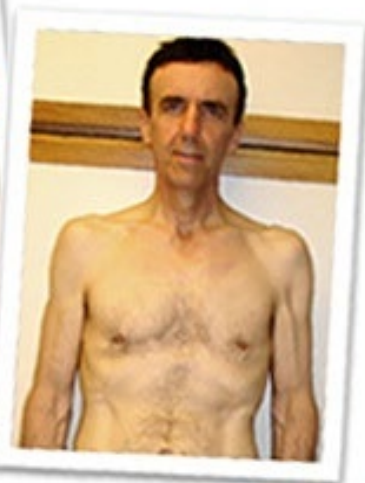(b) Details of hepatopancreatic ampulla



**2004:** Overweight,  
Multiple Health Issues



**2006:** Jaundice  
From Liver Disease



**2014:** 100% RECOVERED  
AND HEALTHY!



# The Big Picture of Digestion.

